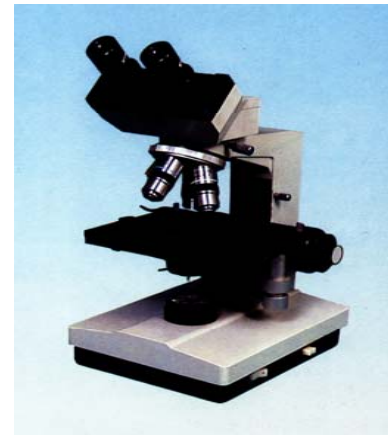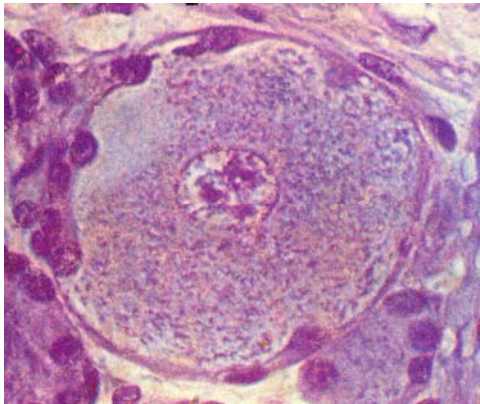



# Histology and Embryology



- Chapter 1 Introduction and Cell**
- Chapter 2 Epithelial tissue**
- Chapter 3 Connective Tissue**
- Chapter 4 Blood**
- Chapter 5 Cartilage and Bone**
- Chapter 6 Muscle Tissue**
- Chapter 7 Nerve Tissue**
- Chapter 8 Circulatory System**
- Chapter 9 Immune System**
- Chapter 10 Skin**
- Chapter 11 Digestive Tract**
- Chapter 12 Digestive Gland**
- Chapter 13 Respiratory System**
- Chapter 14 Urinary System**
- Chapter 15 Endocrine System**
- Chapter 16 Sense Organ**
- Chapter 17 Male Reproduction**
- Chapter 18 Female Reproduction**
- Chapter 19 Embryology 1**
- Chapter 20**

# Chapter 7 Nerve Tissue

## I Slides

## **II Sections**

NO.13 spinal cord

NO.20 sciatic nerve

NO.21 sciatic nerve

NO.22 tactile corpuscle

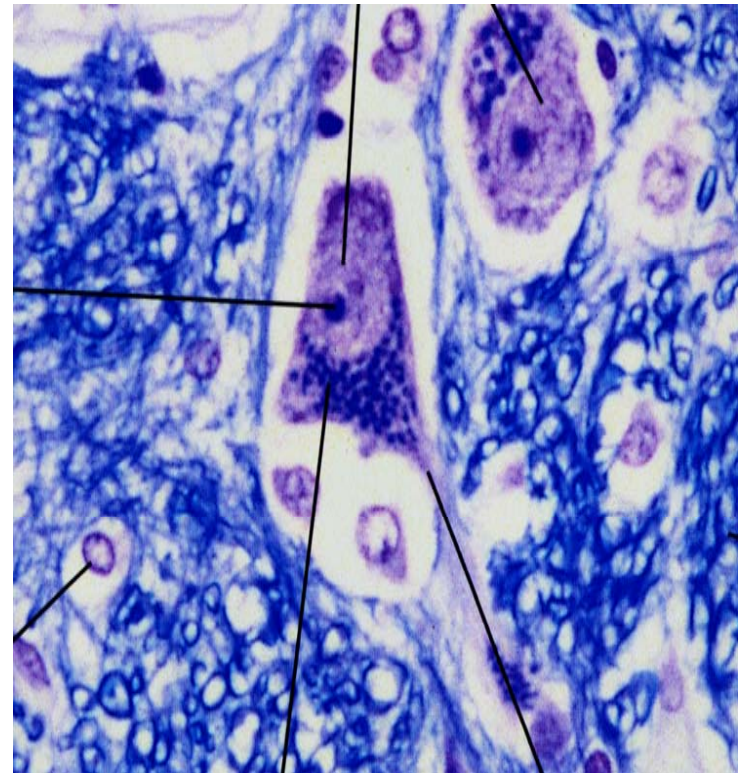
NO.45 lamellar corpuscle

NO.23 motor end plate

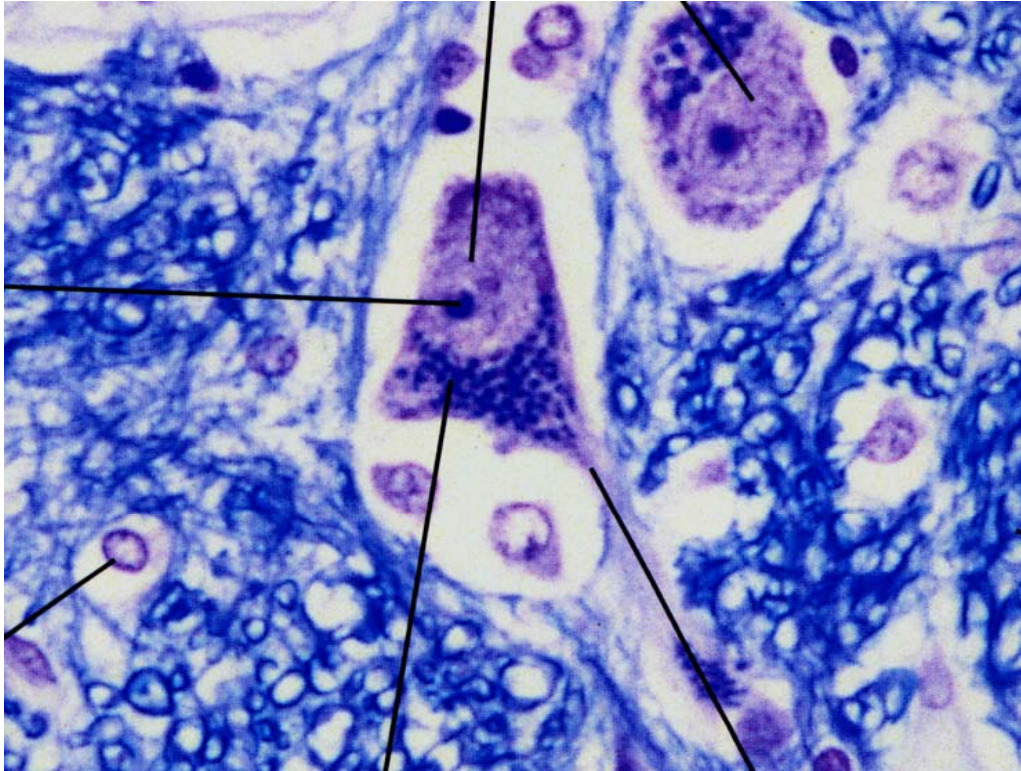
## III Drawing:neron

## **IV EM photos: 26-31**

## V Summary



### III Drawing:neuron



**Material :**

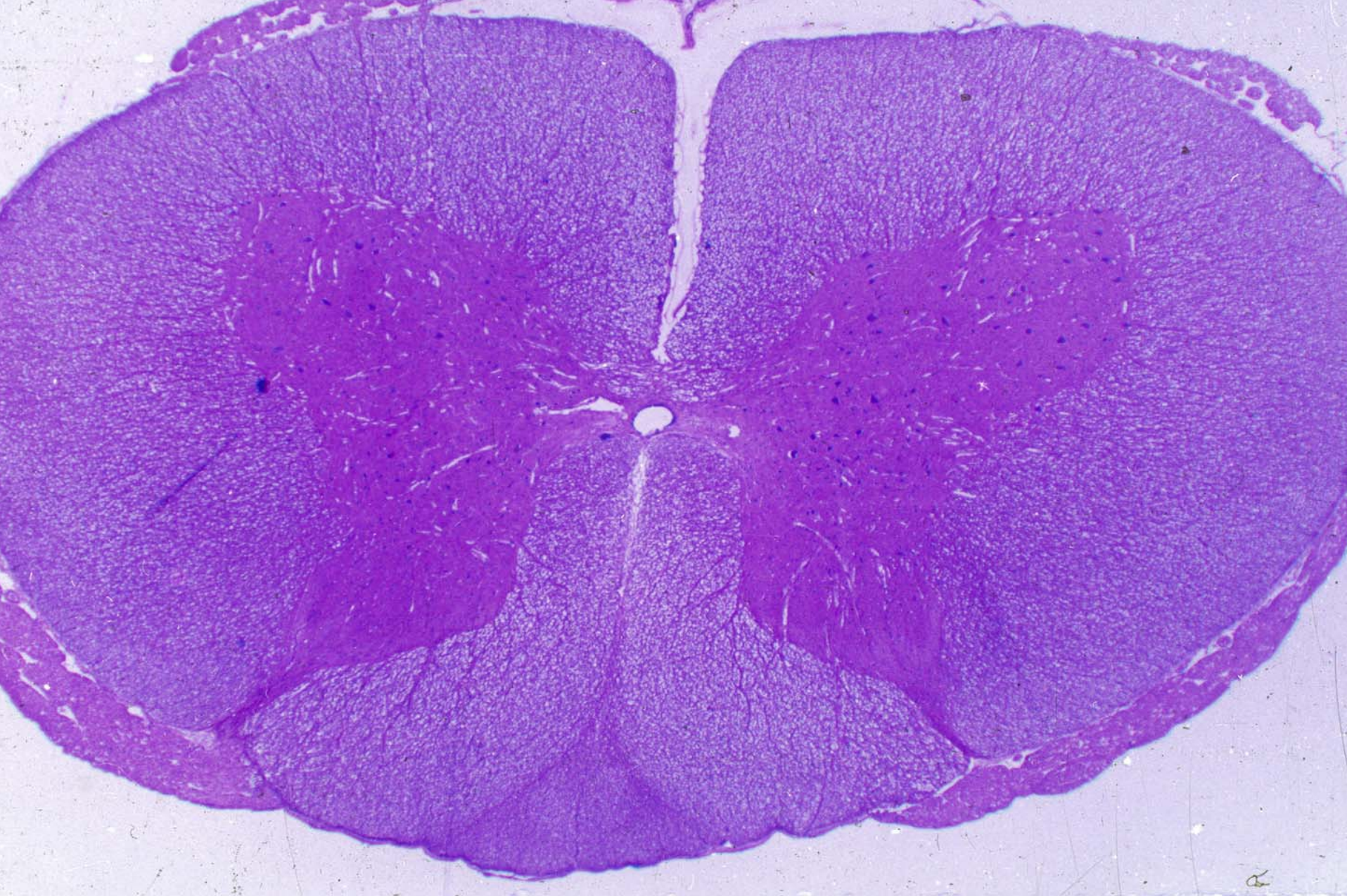
**Staining :**

**Amplification :**

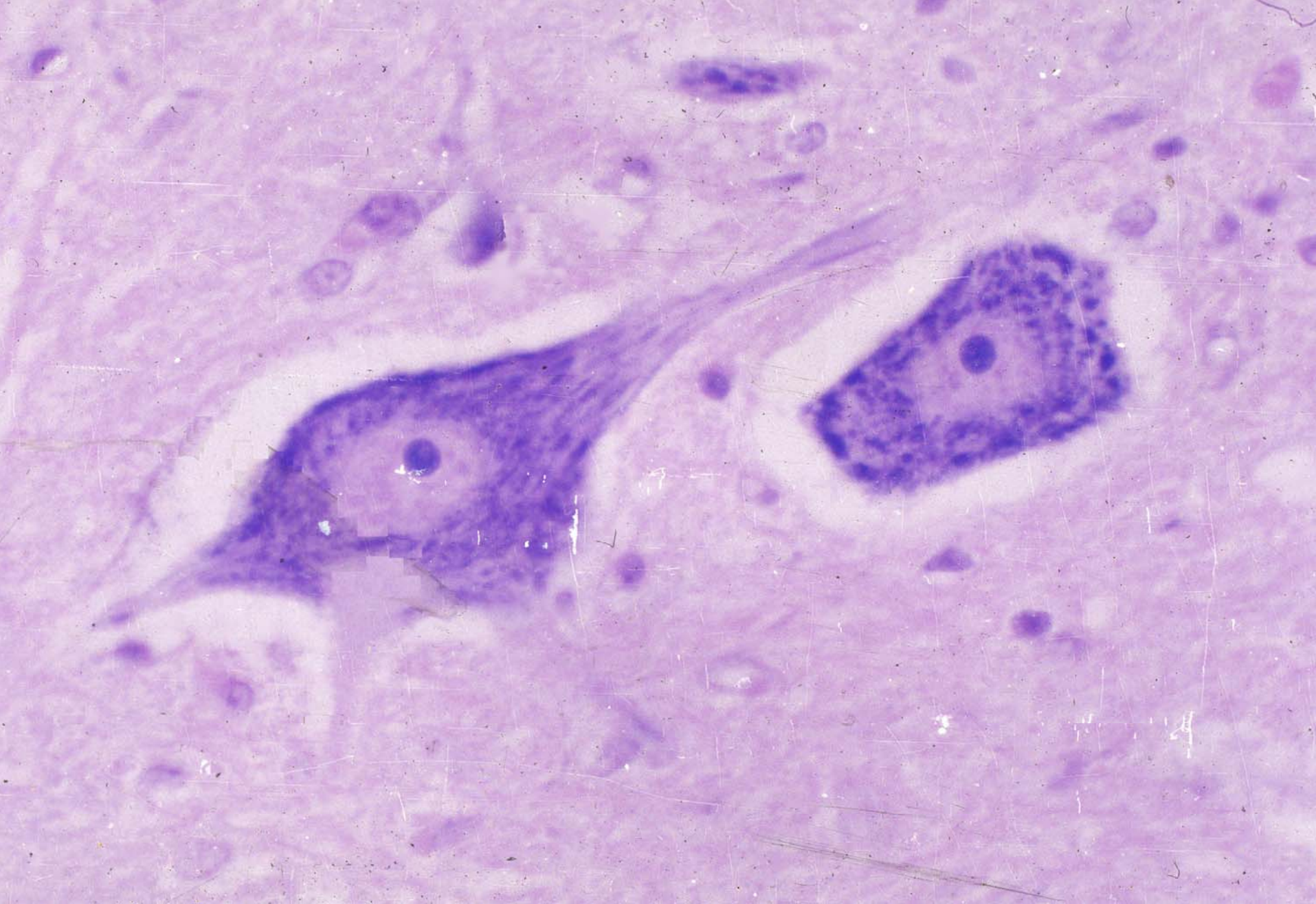
**Date :**

## V. Summary:

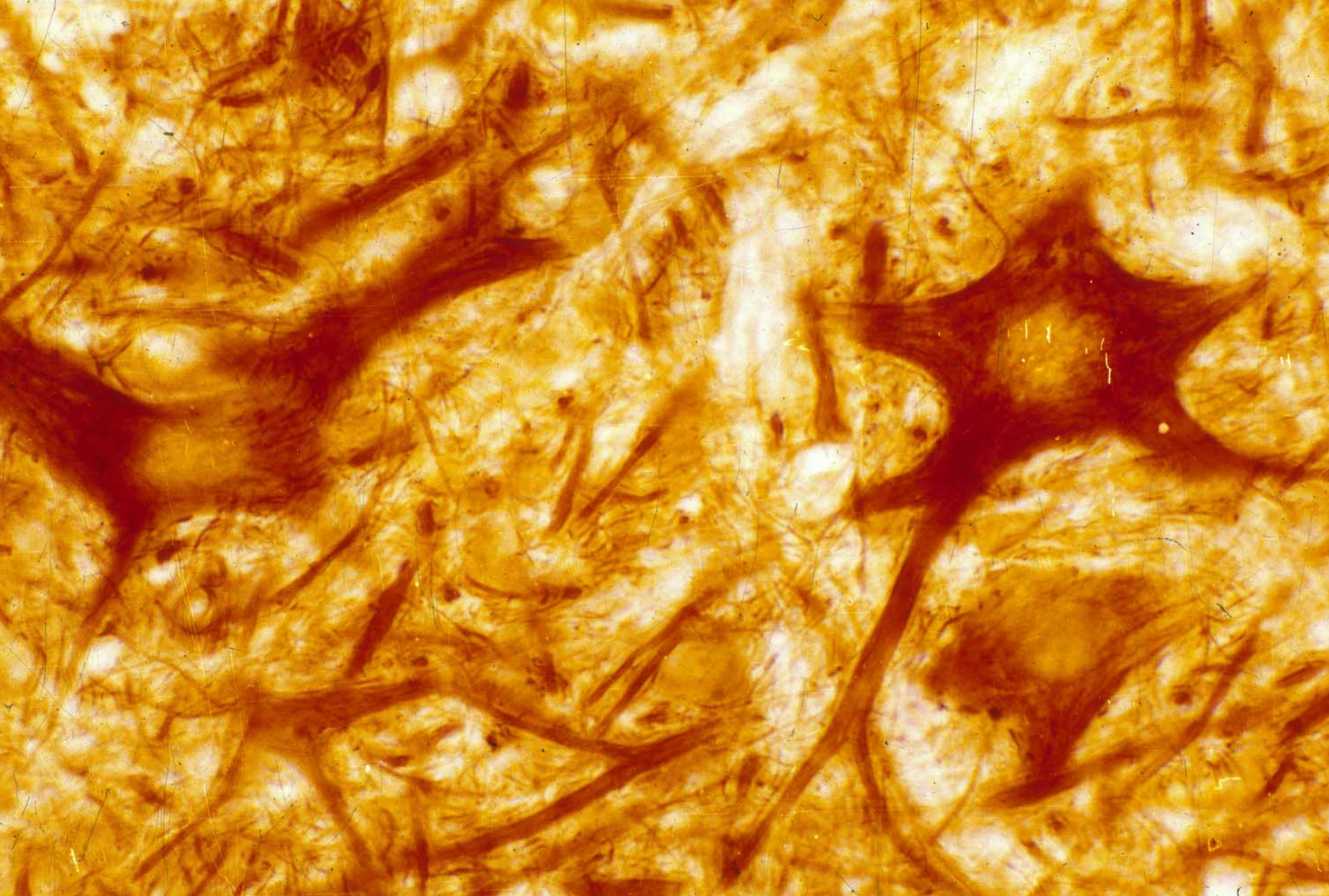
- The structure and function of neuron, nerve
- The type of neuroglia cell
- The ultra structure of synapse
- The structure and type of nerve fiber
- The structure of motor end plate



**spinal cord**

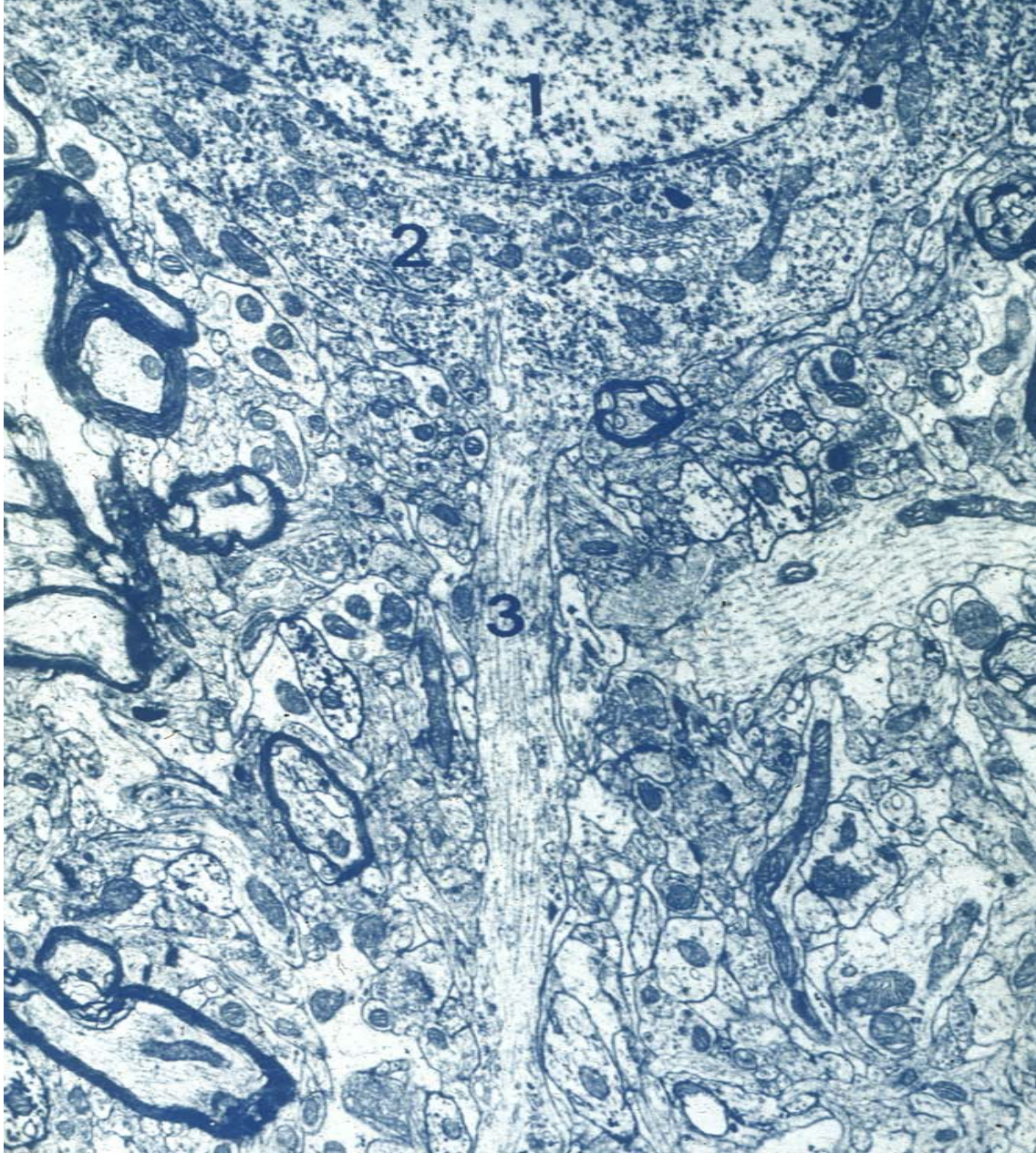


**neuron**

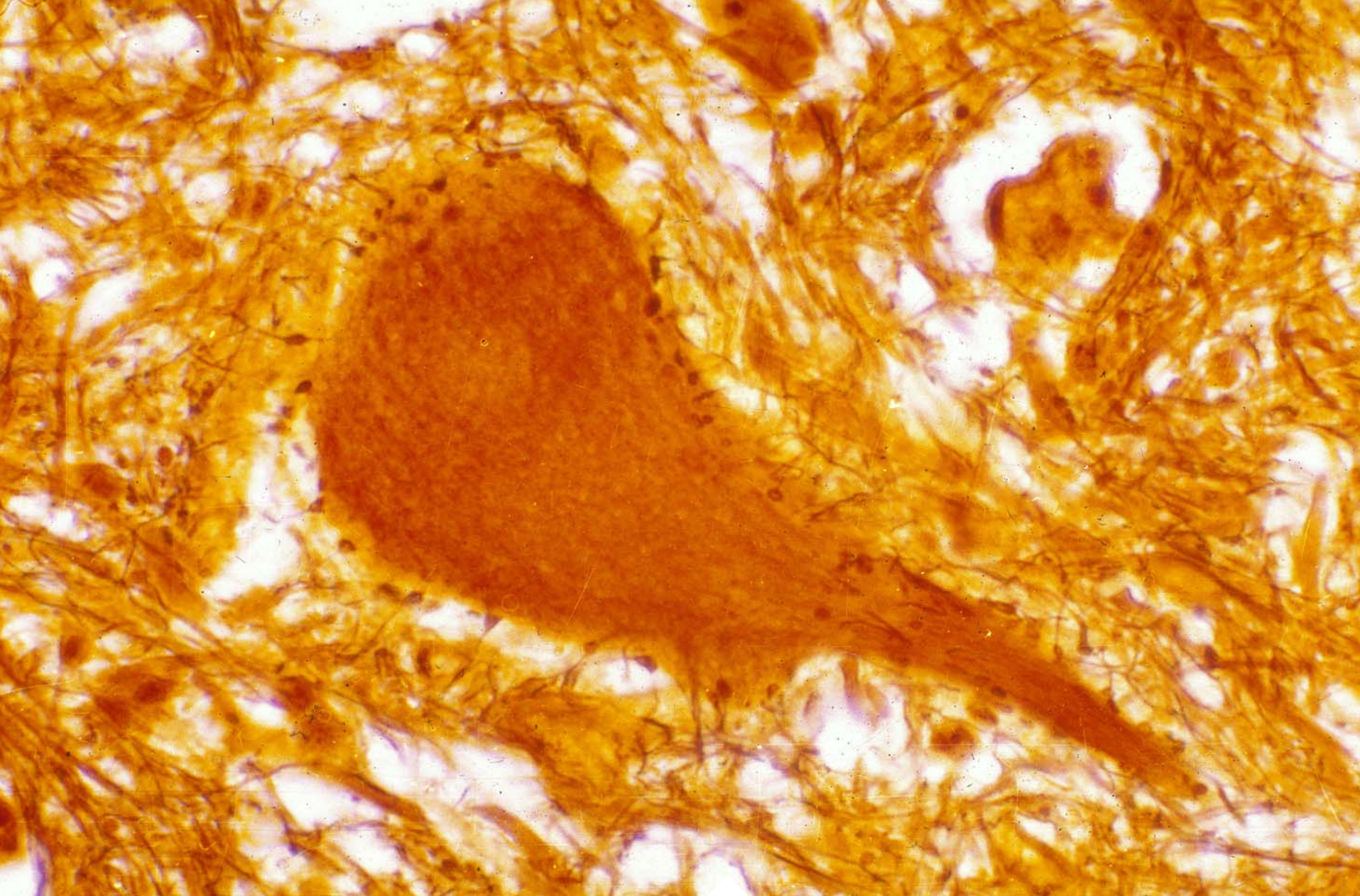


**neuron**

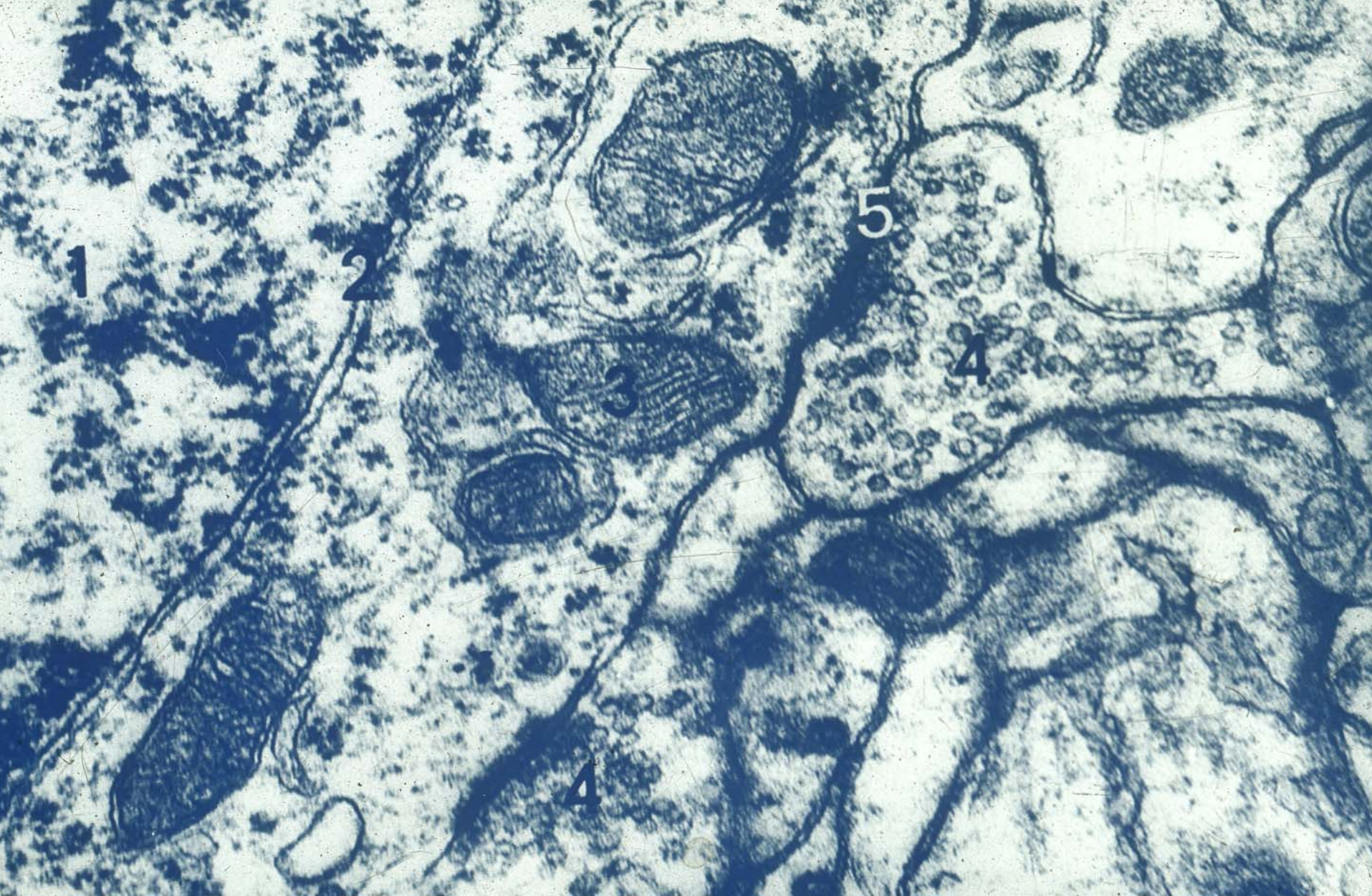




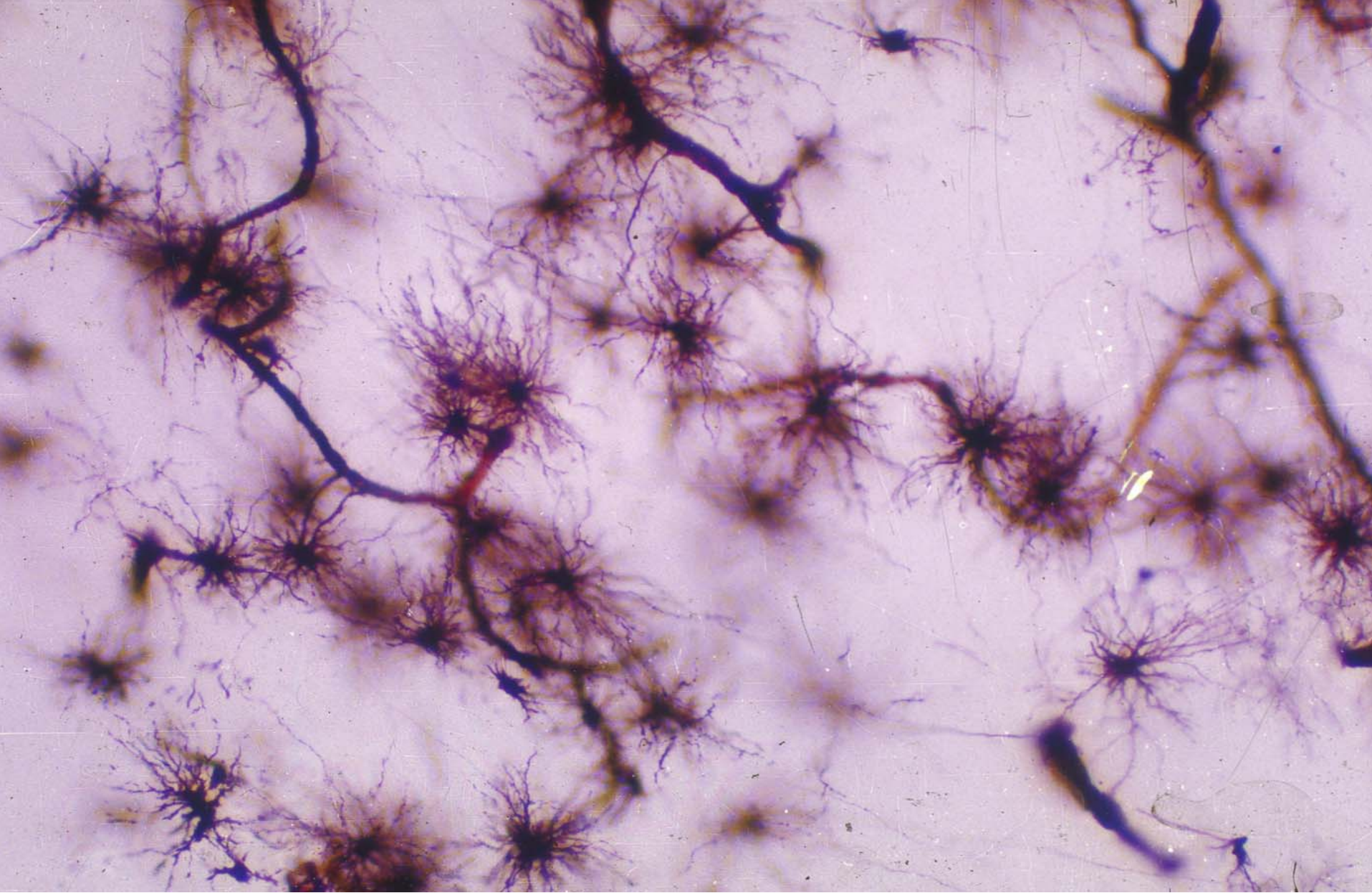
**dendrite**



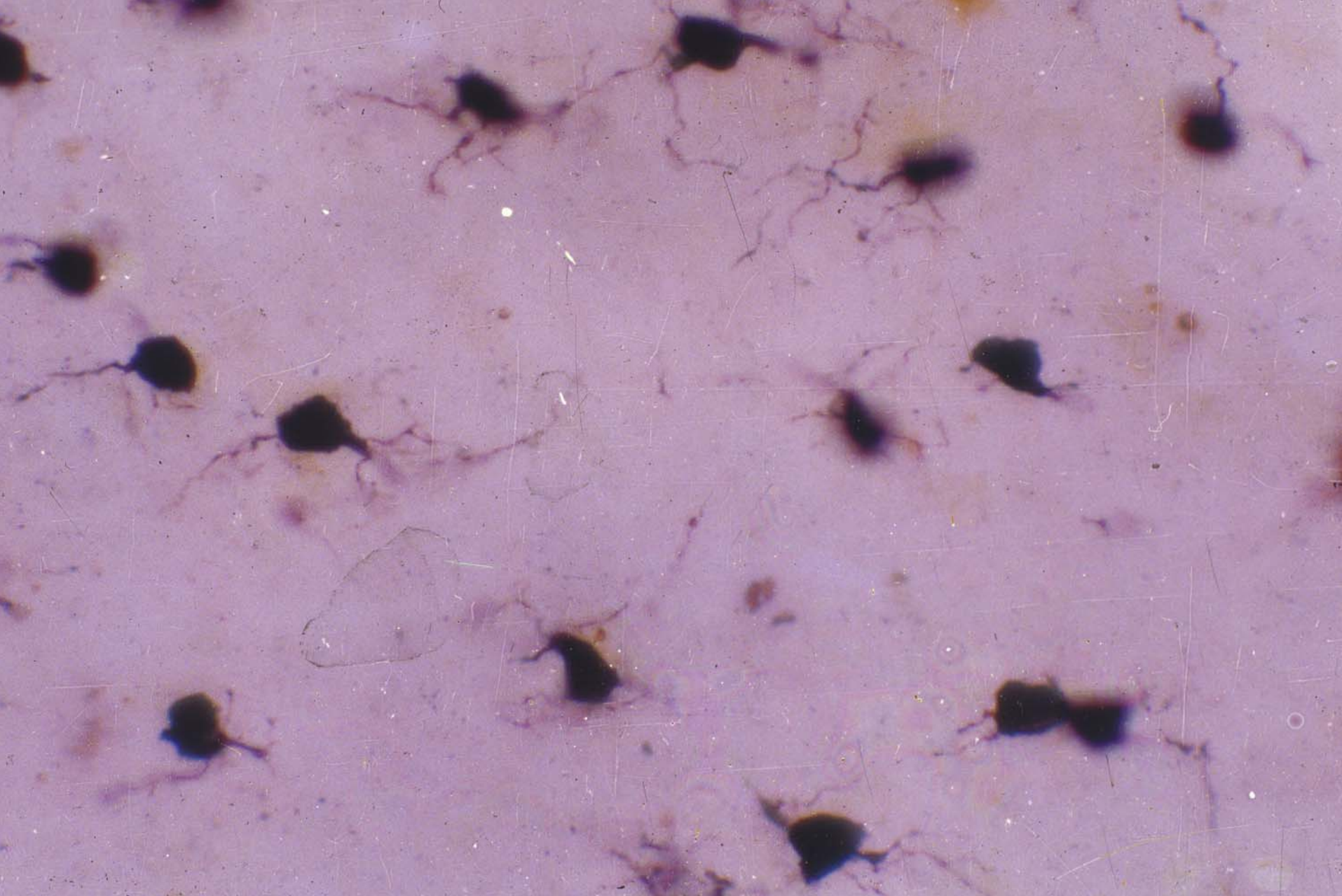
**synapse**



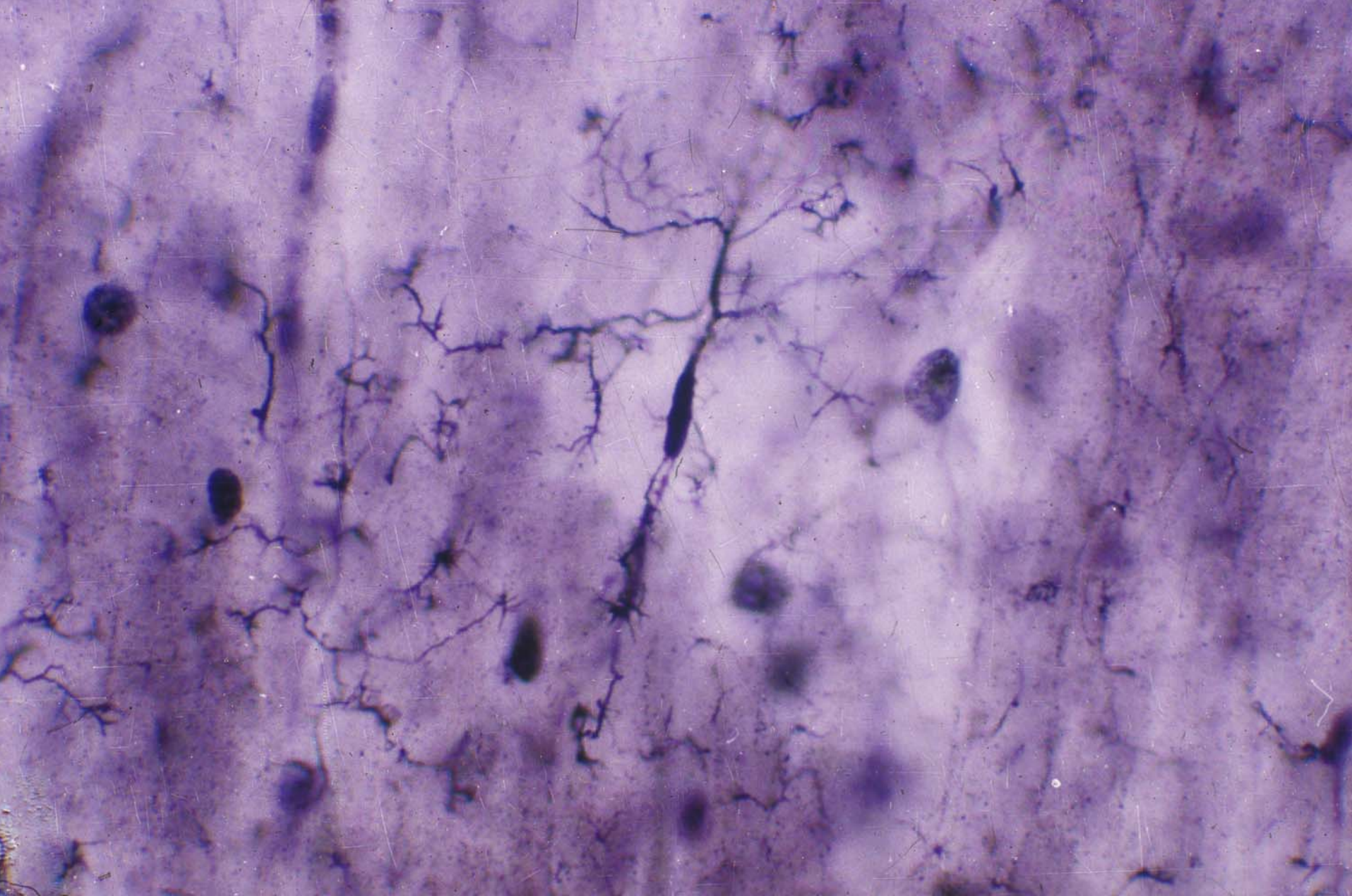
**synapse**



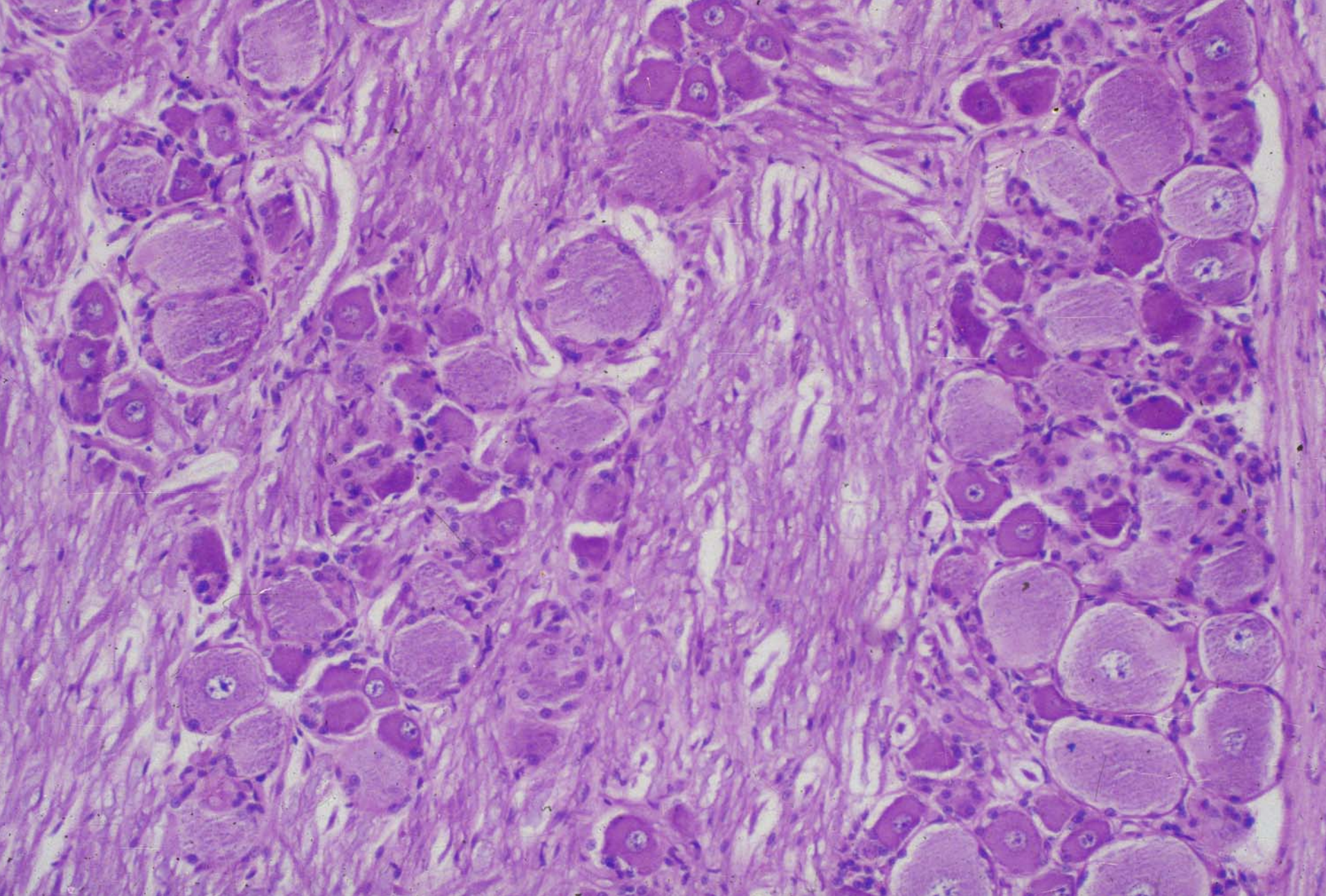
**astrocyte**



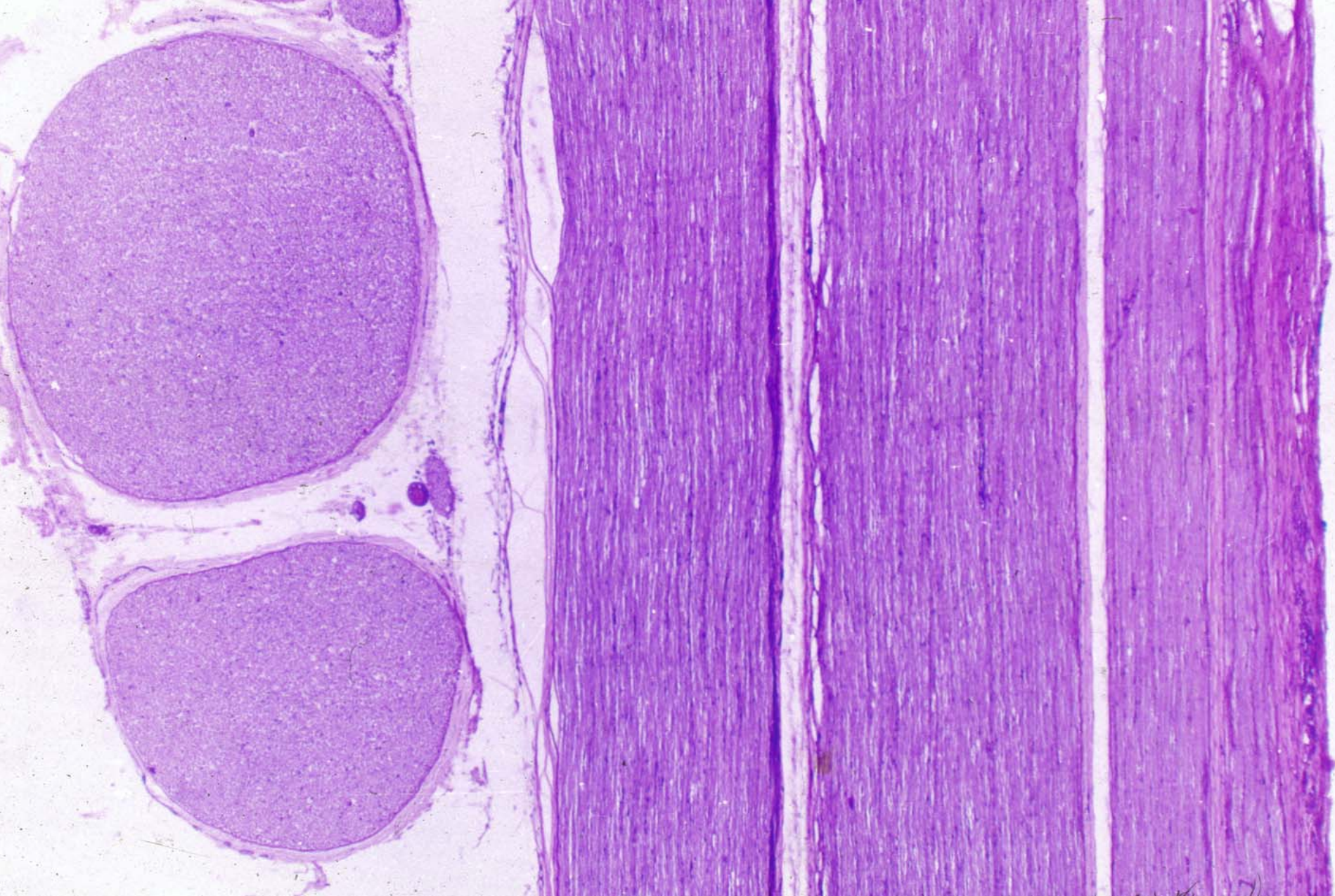
**oligodendrocyte**



**microglia**

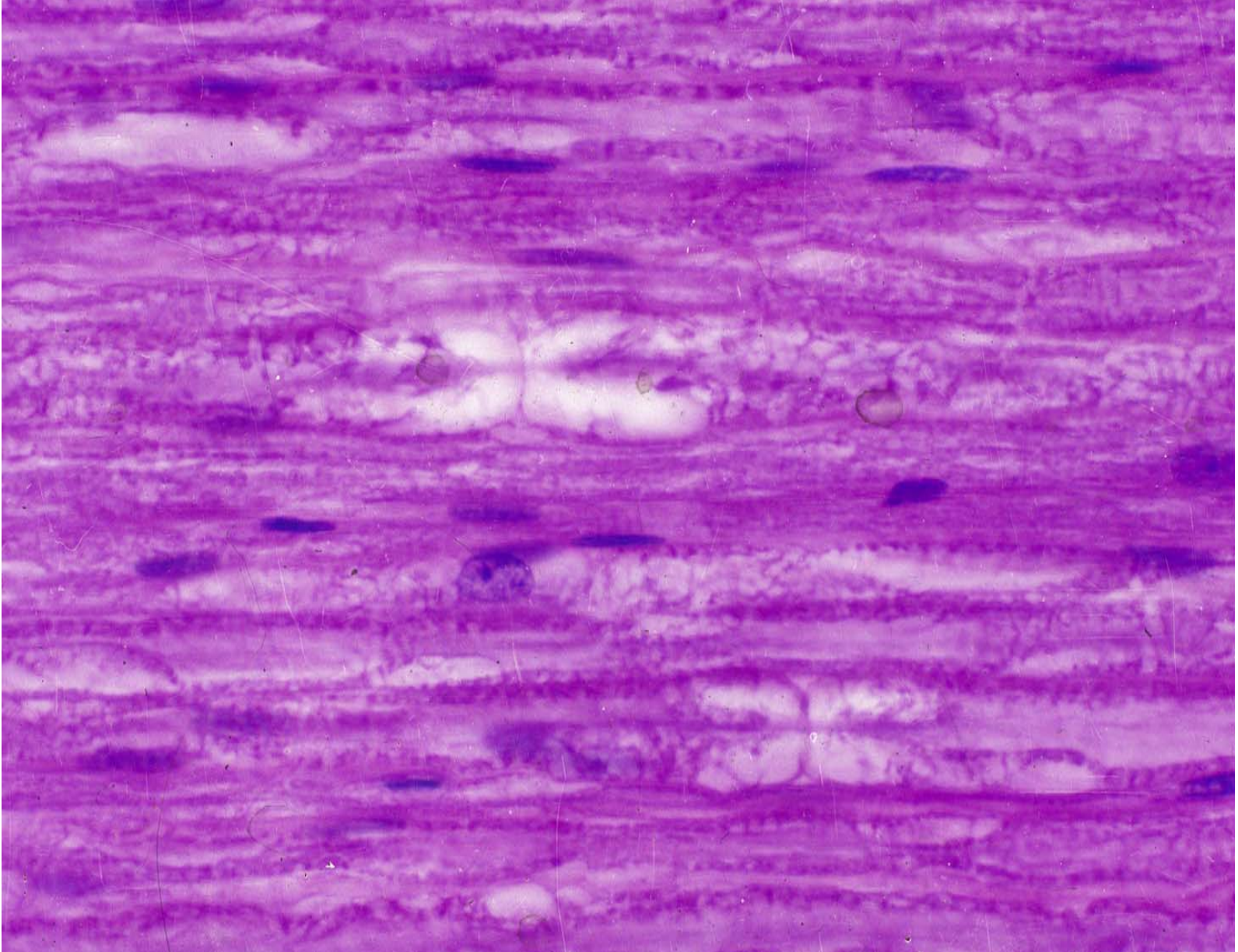


**satellite cell**

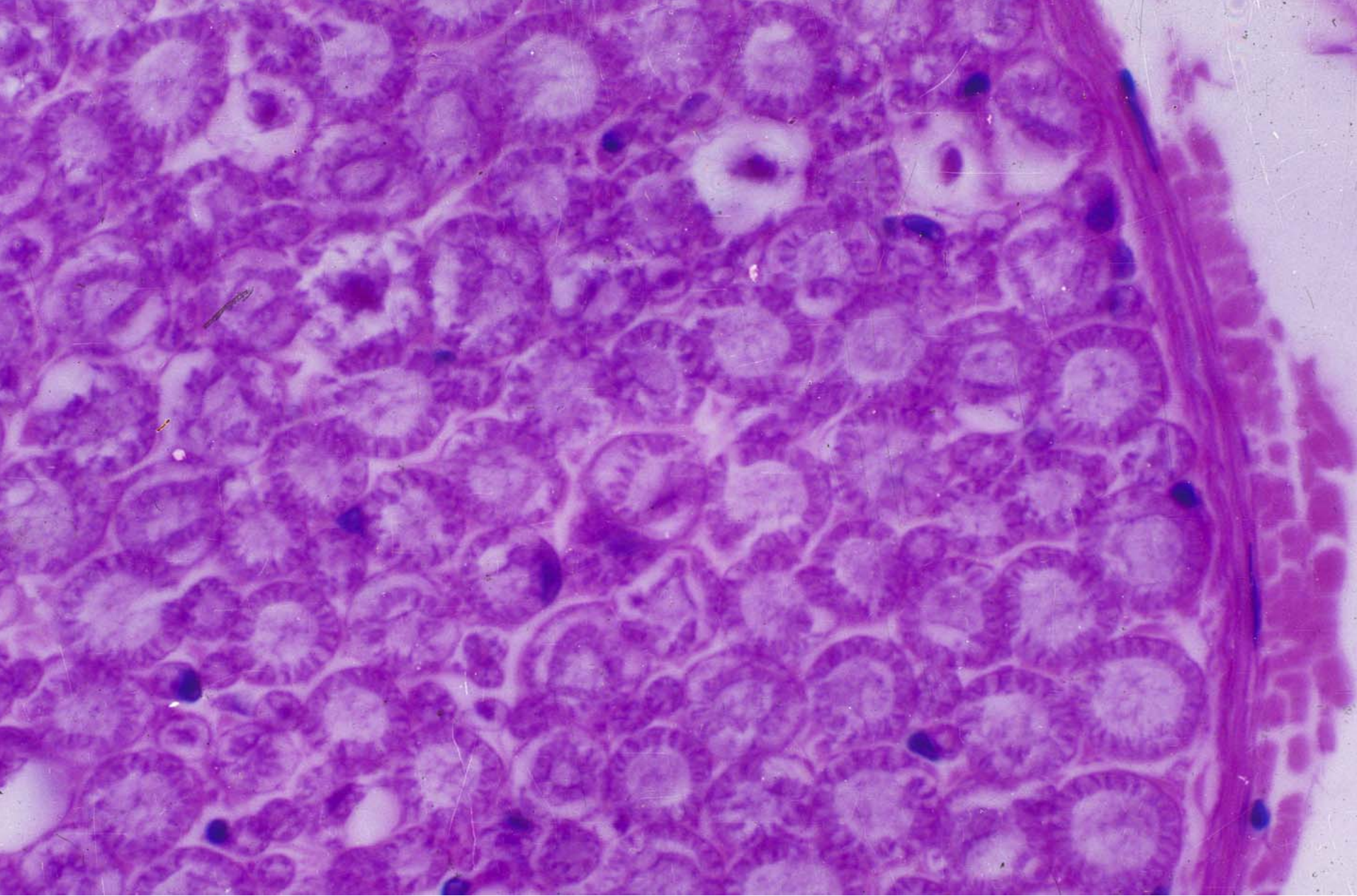


**nerve**

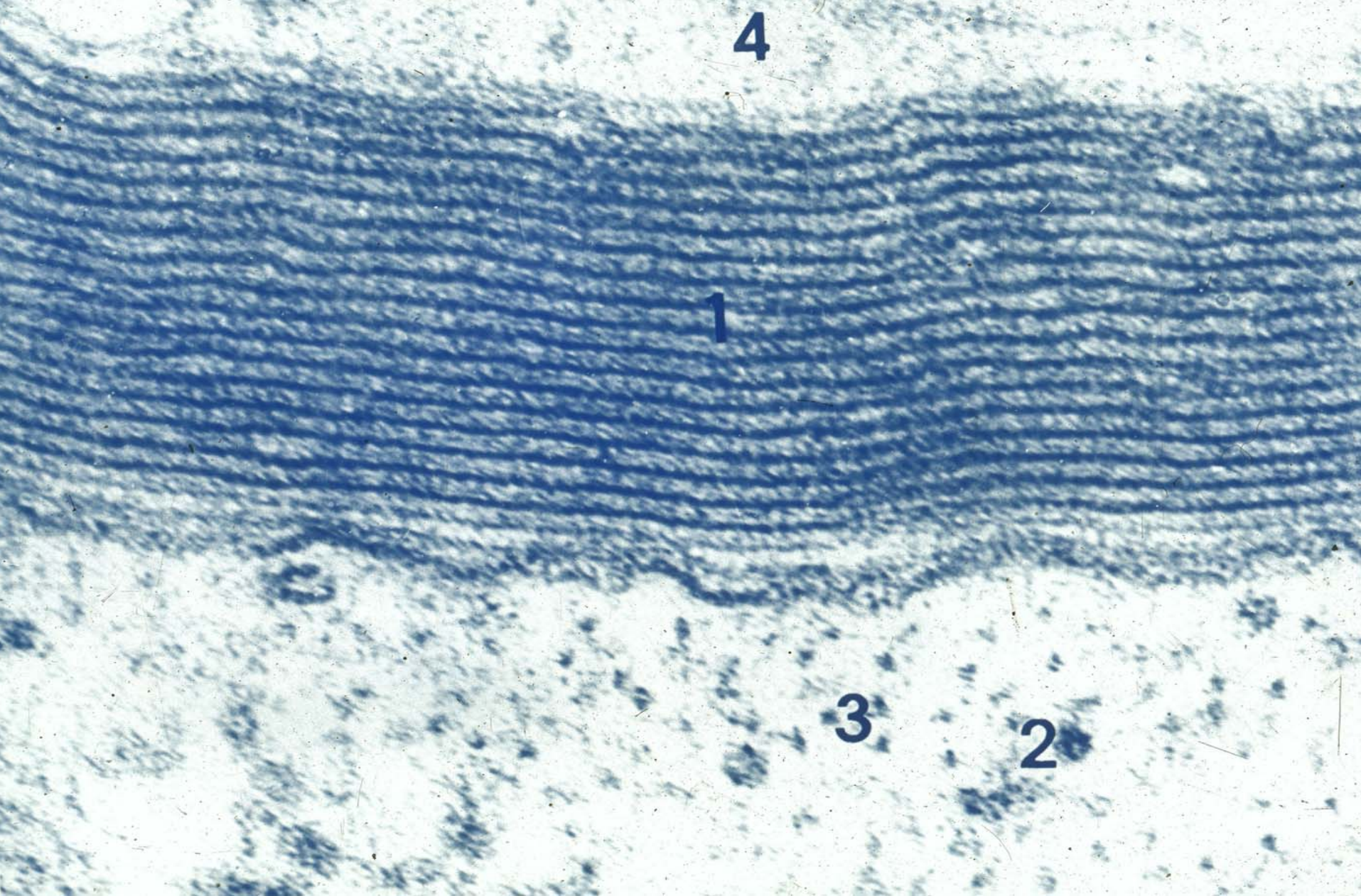




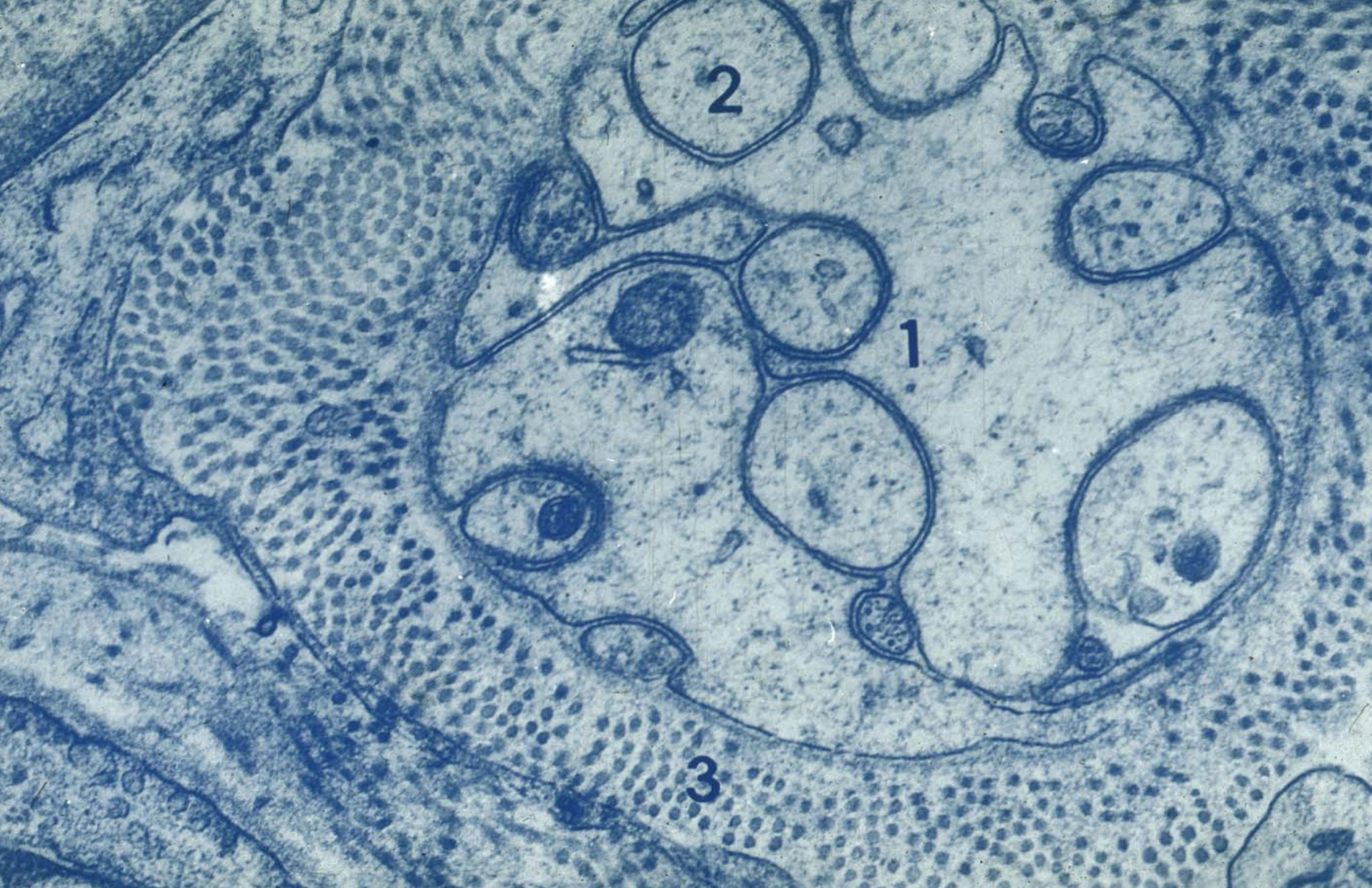
**myelinated nerve fiber**



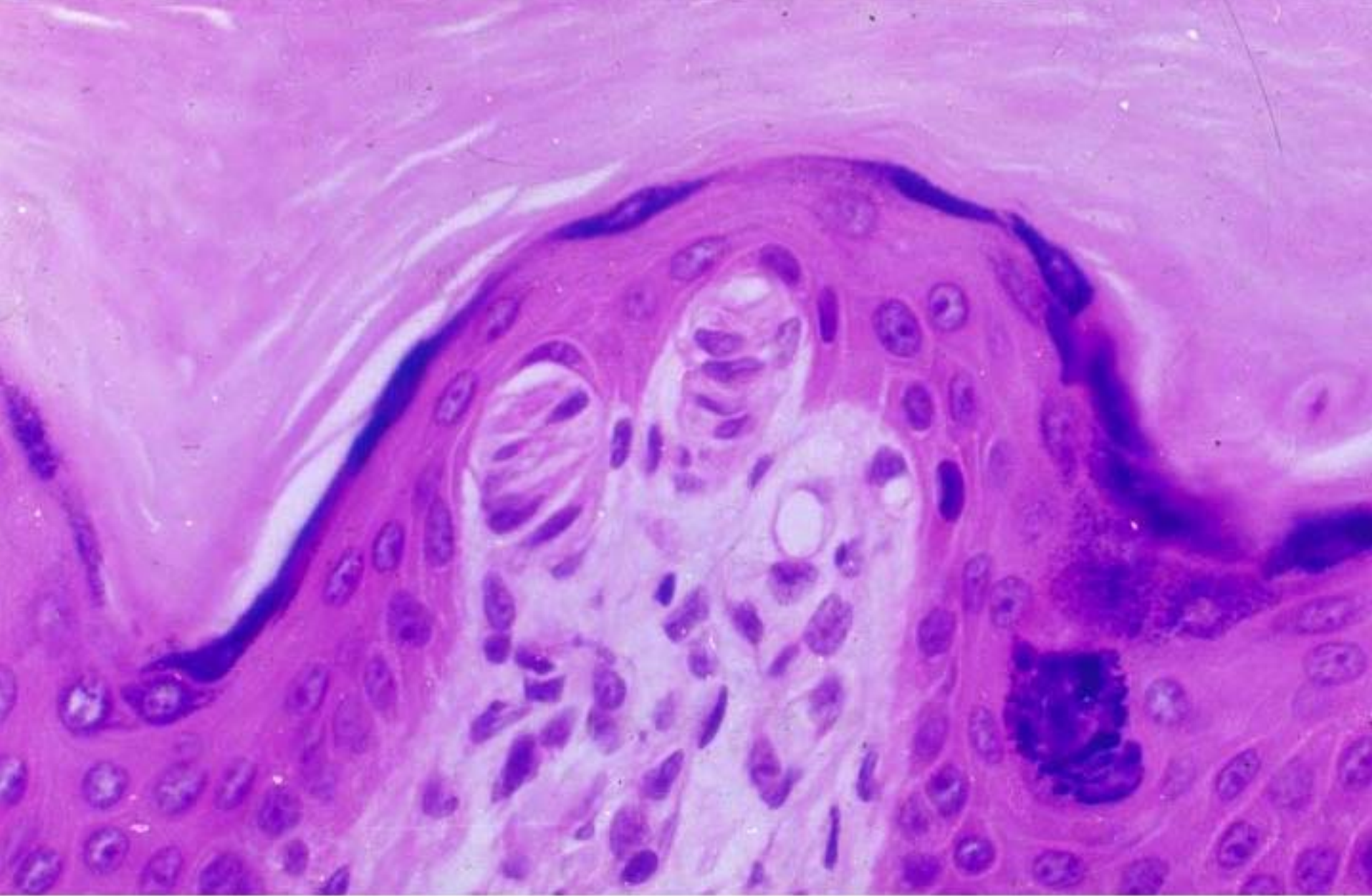
**nerve fiber**



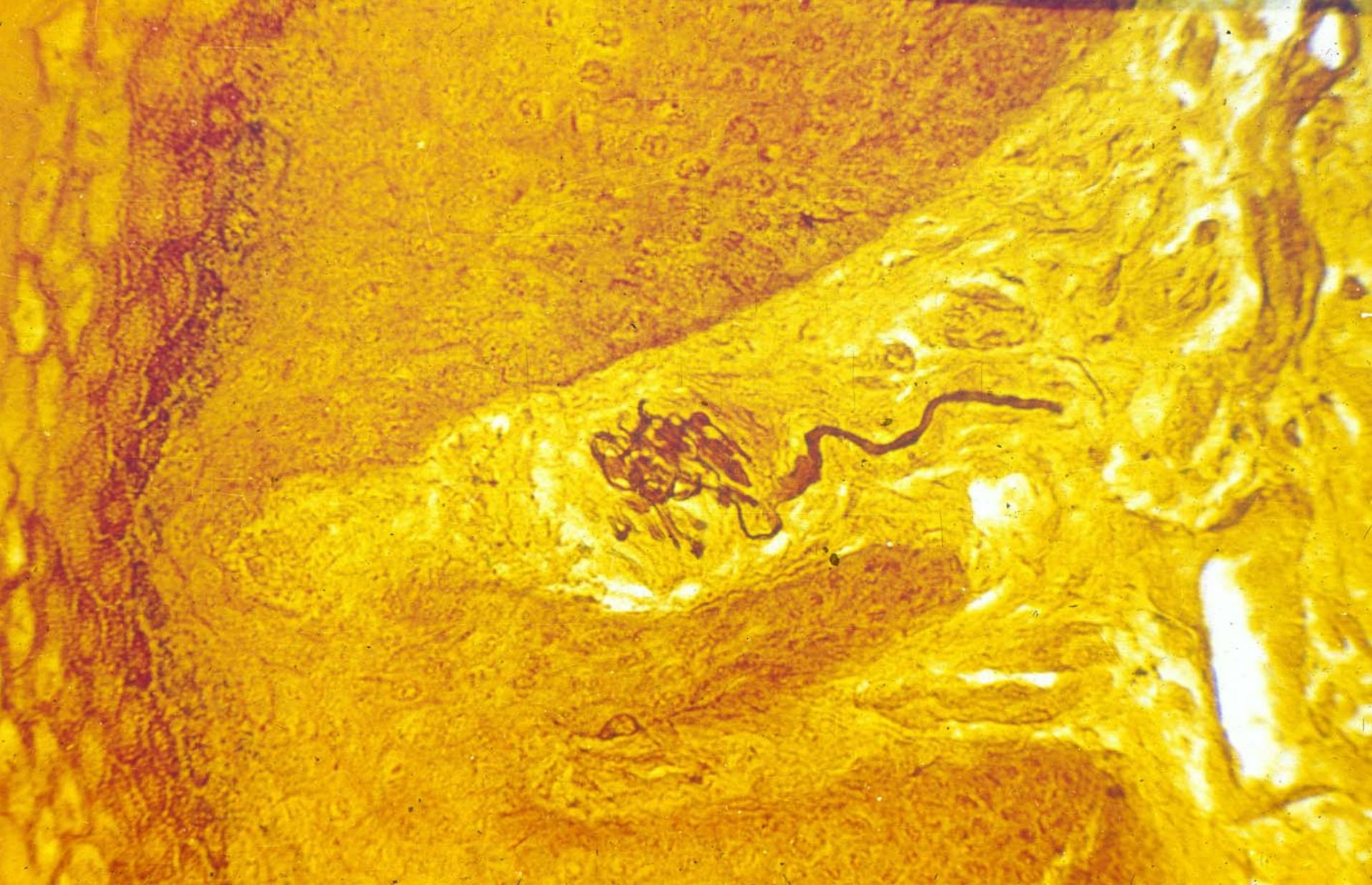
**myelinated nerve fiber**



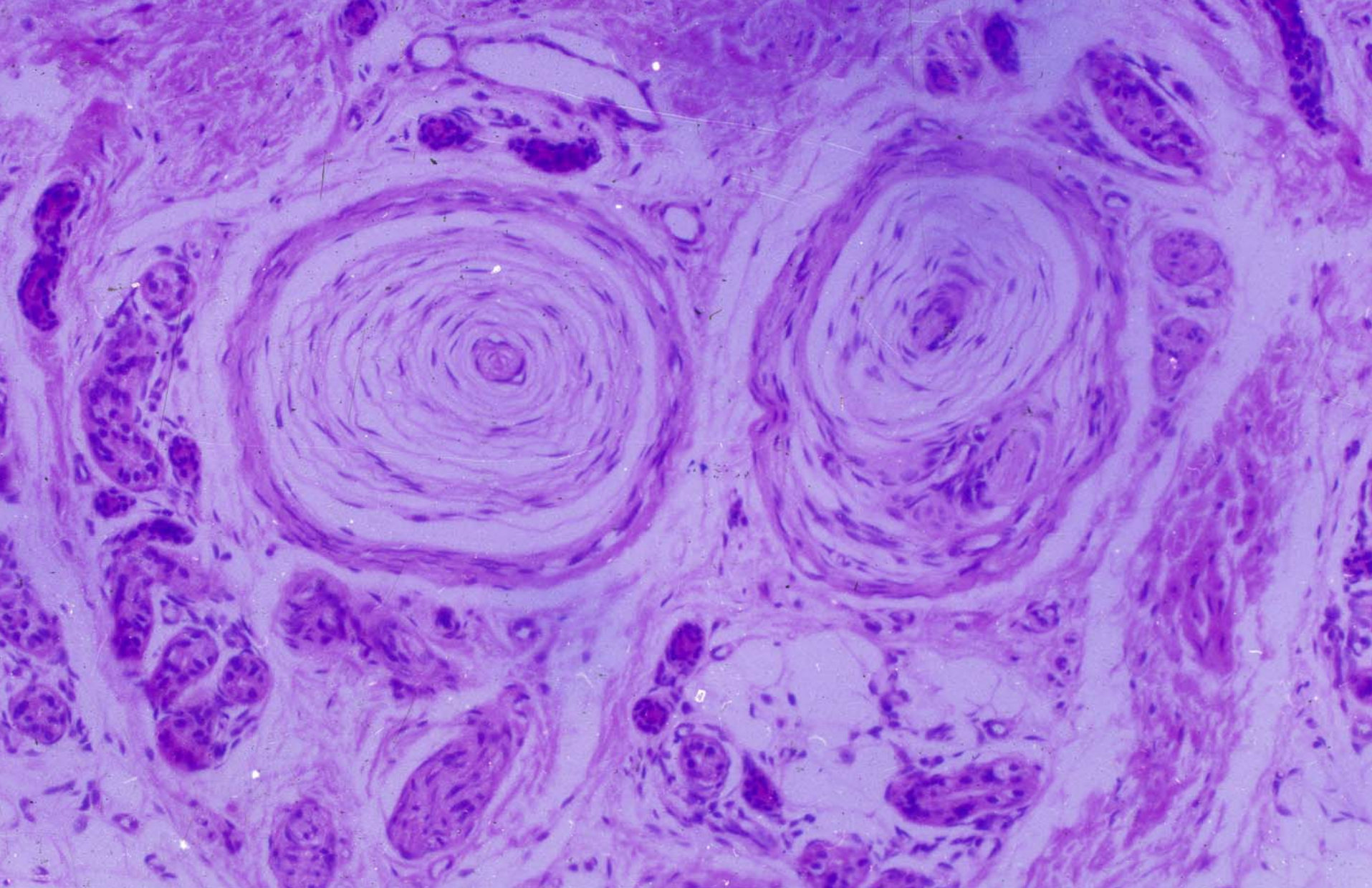
**unmyelinated nerve fiber**



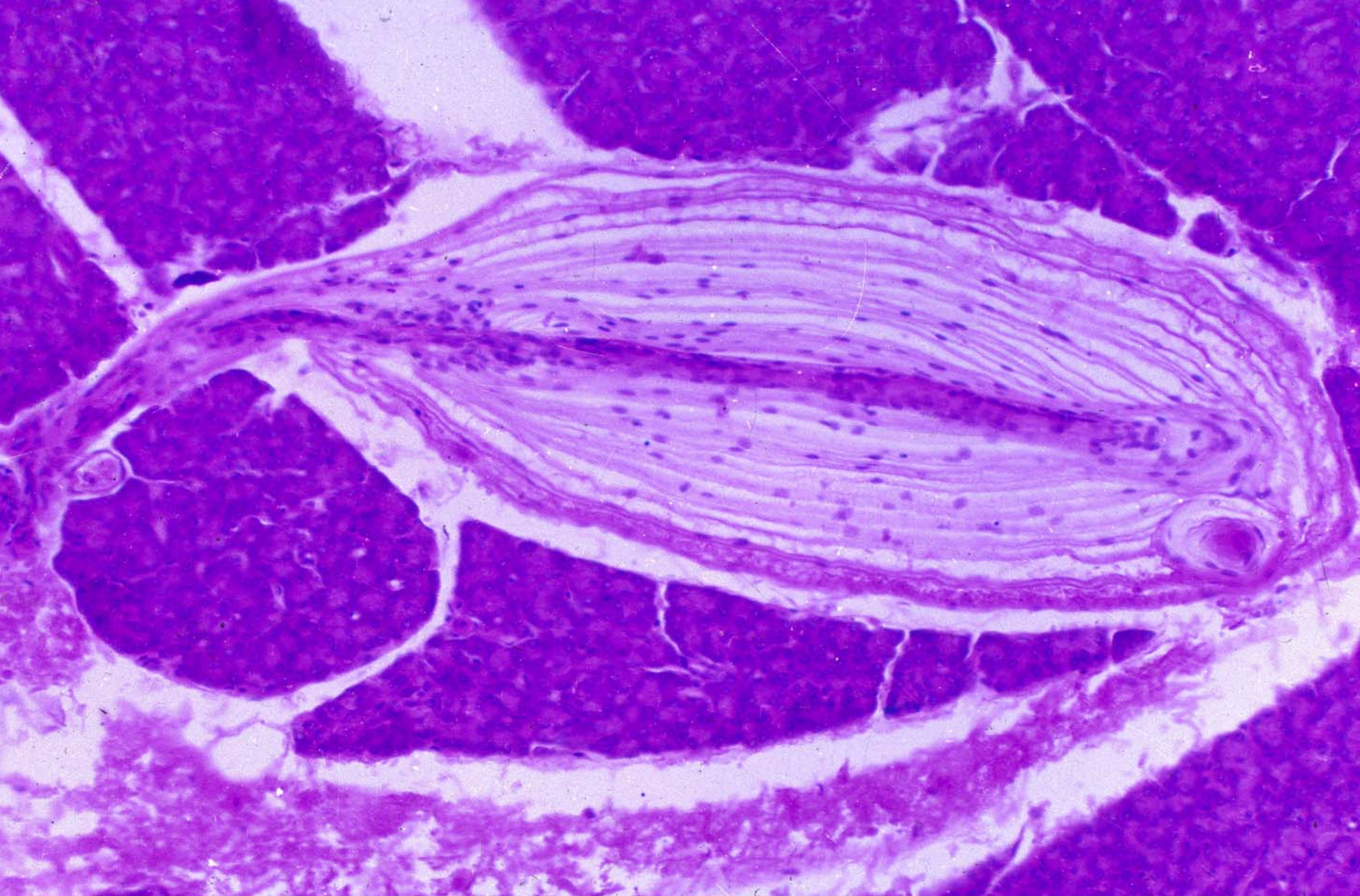
**tactile corpuscle**



**tactile corpuscle**

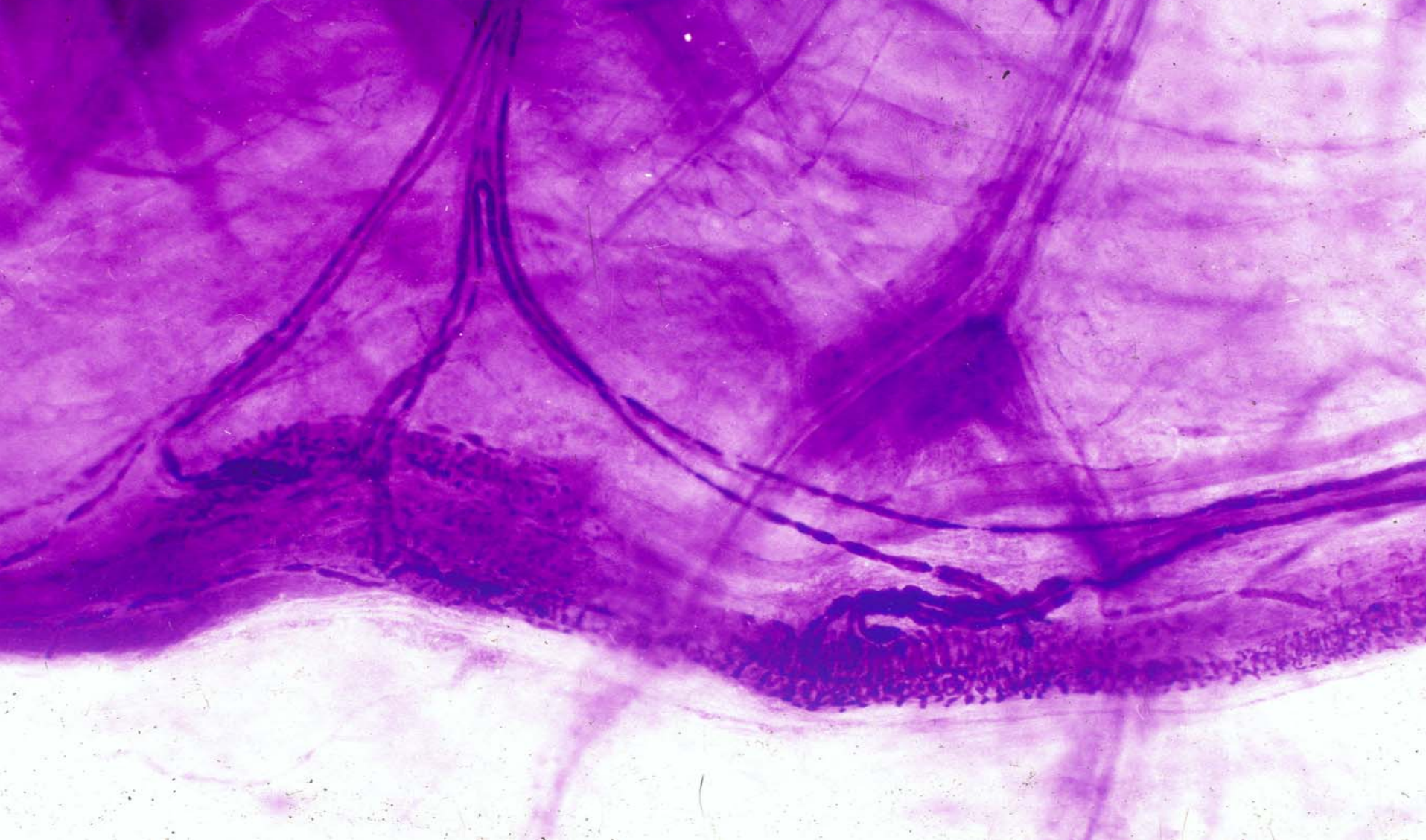


**lamellar corpuscle**

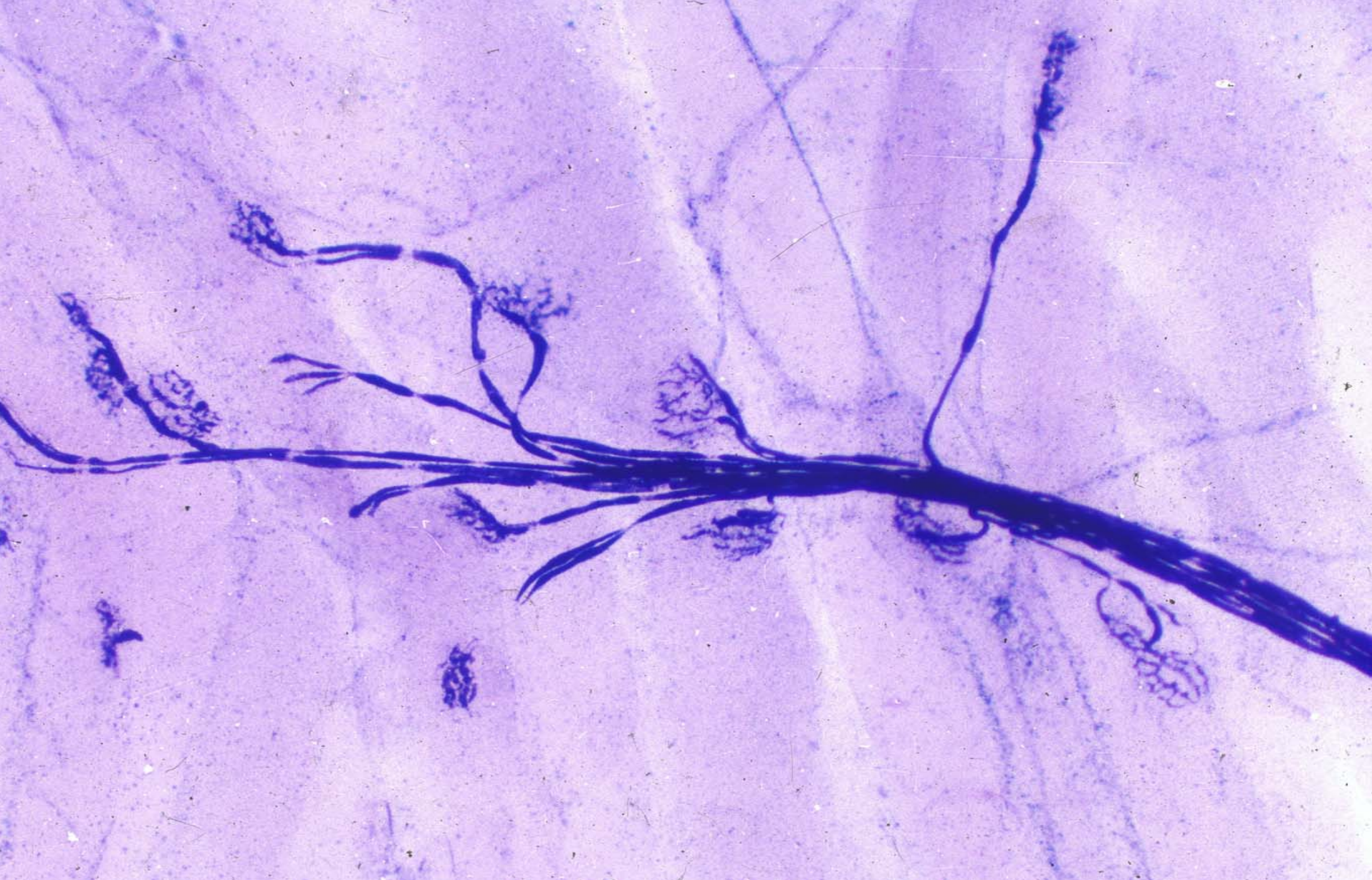


**lamellar corpuscle**

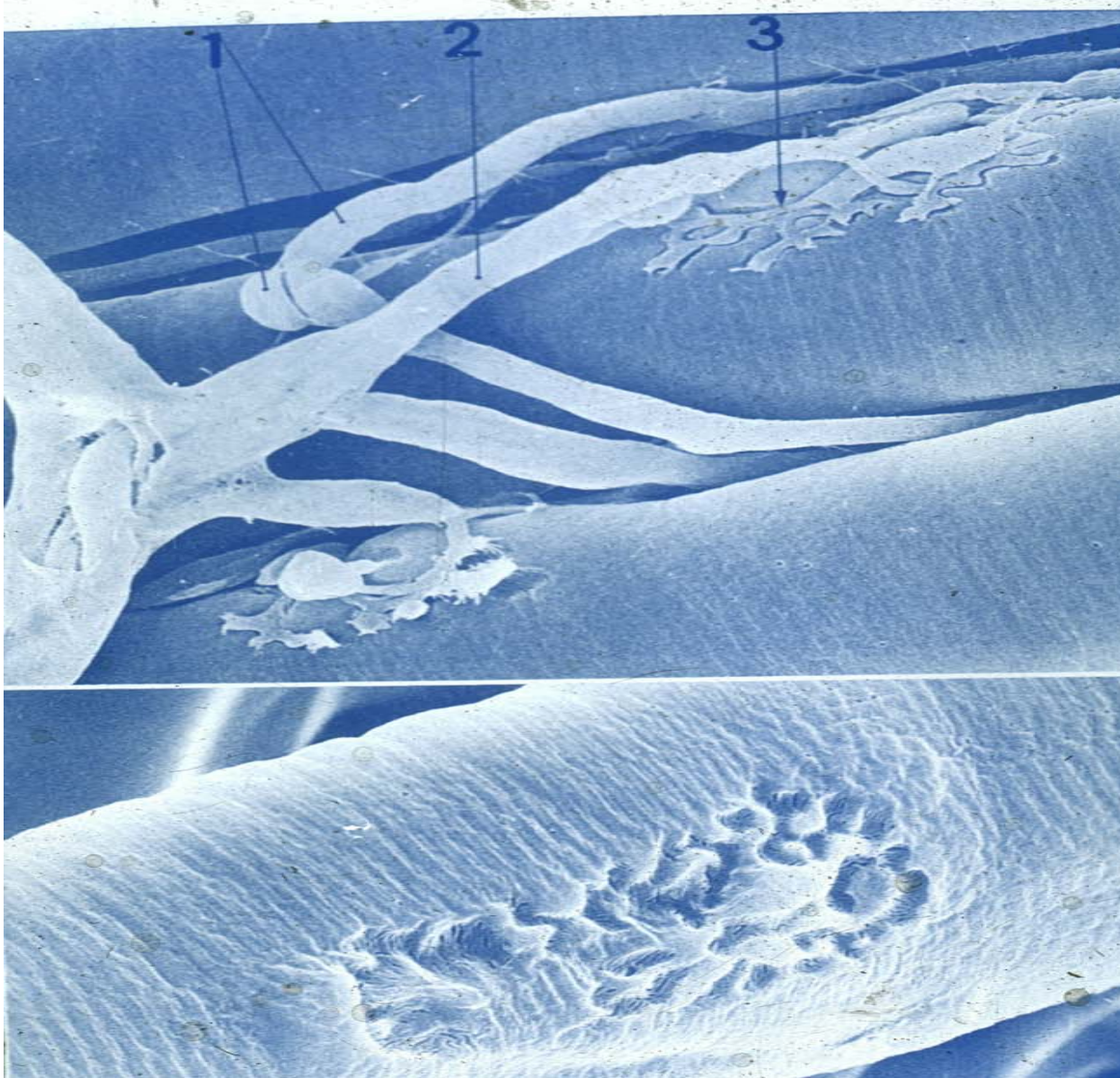




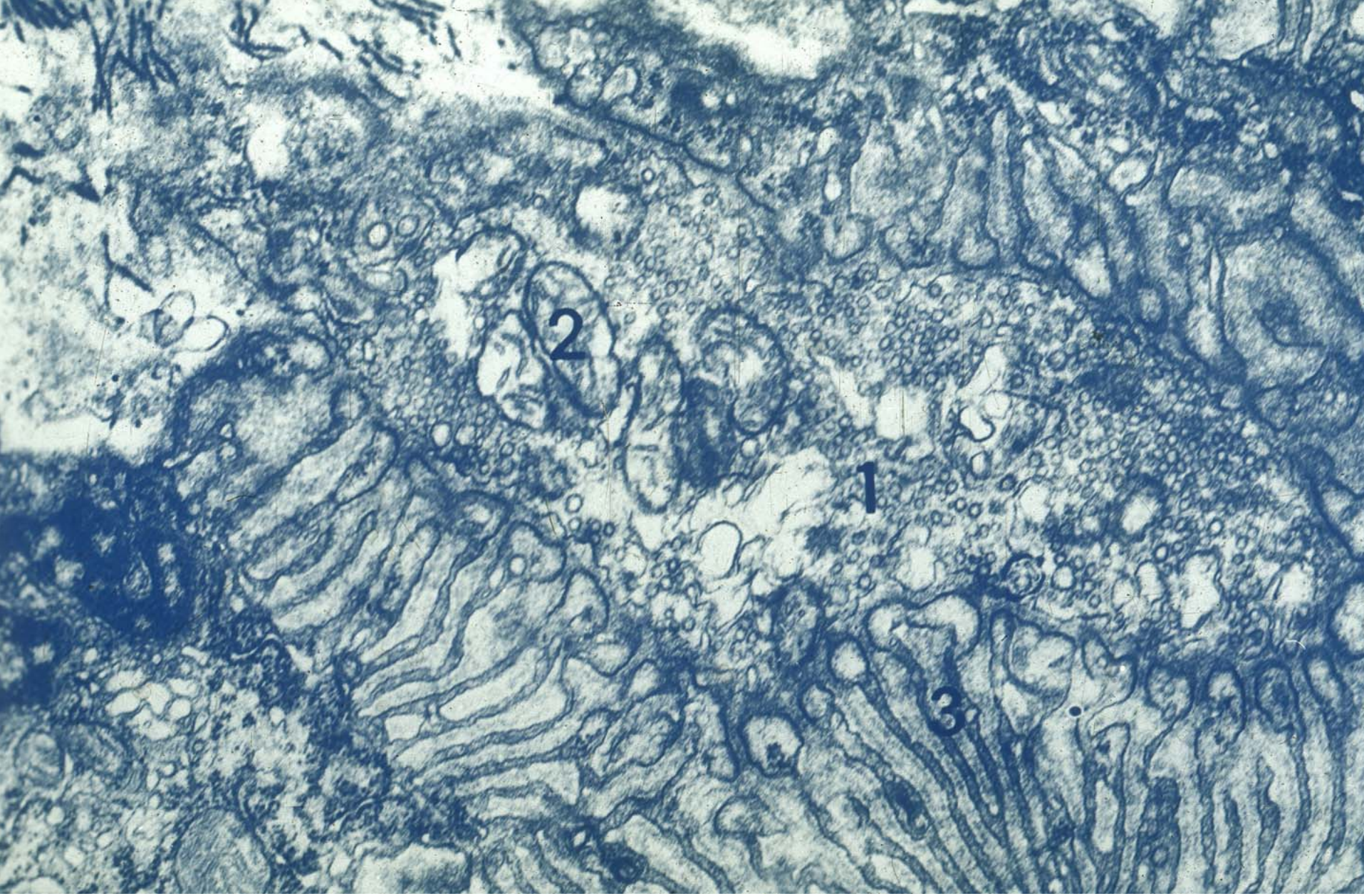
**muscle spindle**



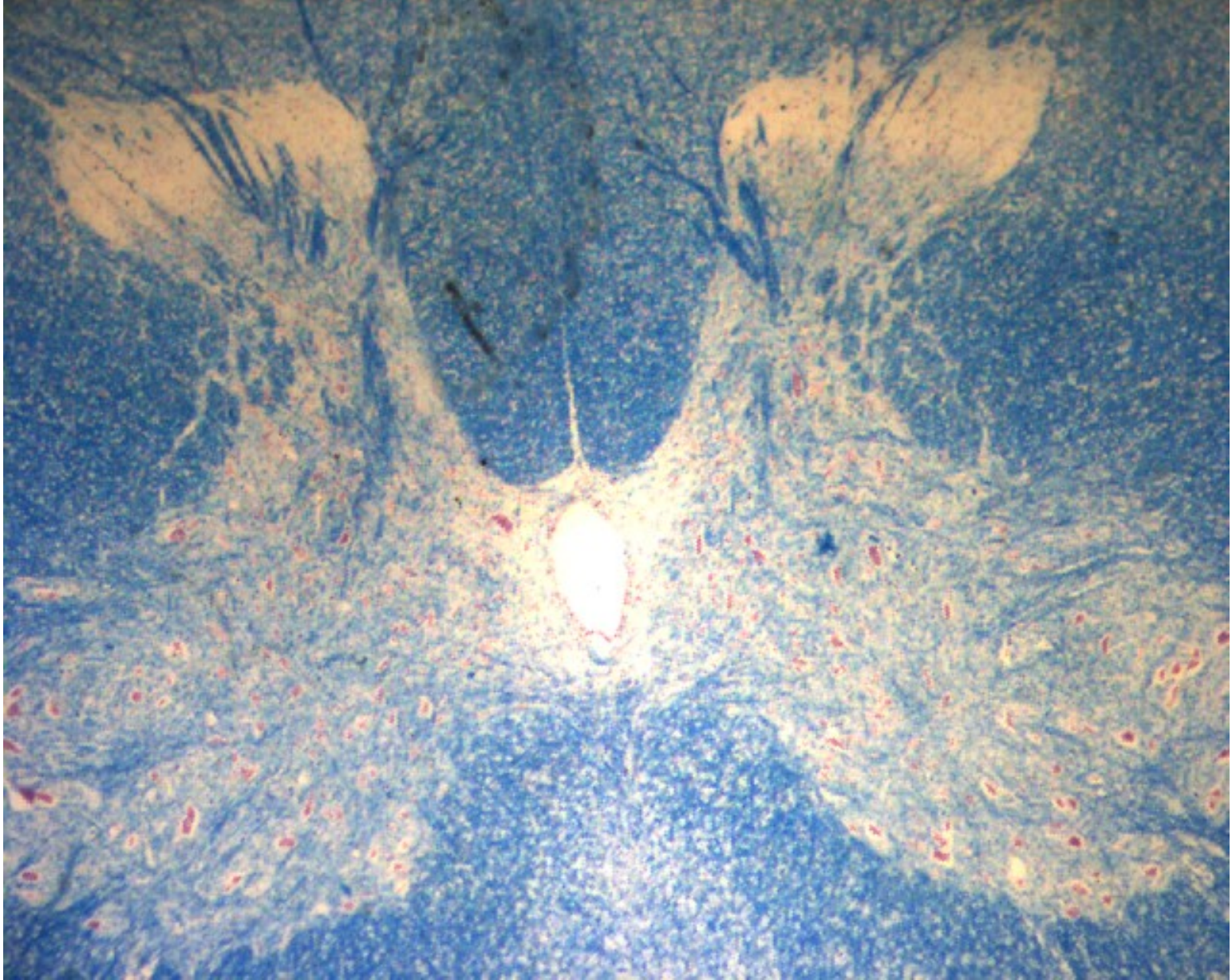
**motor end plate**



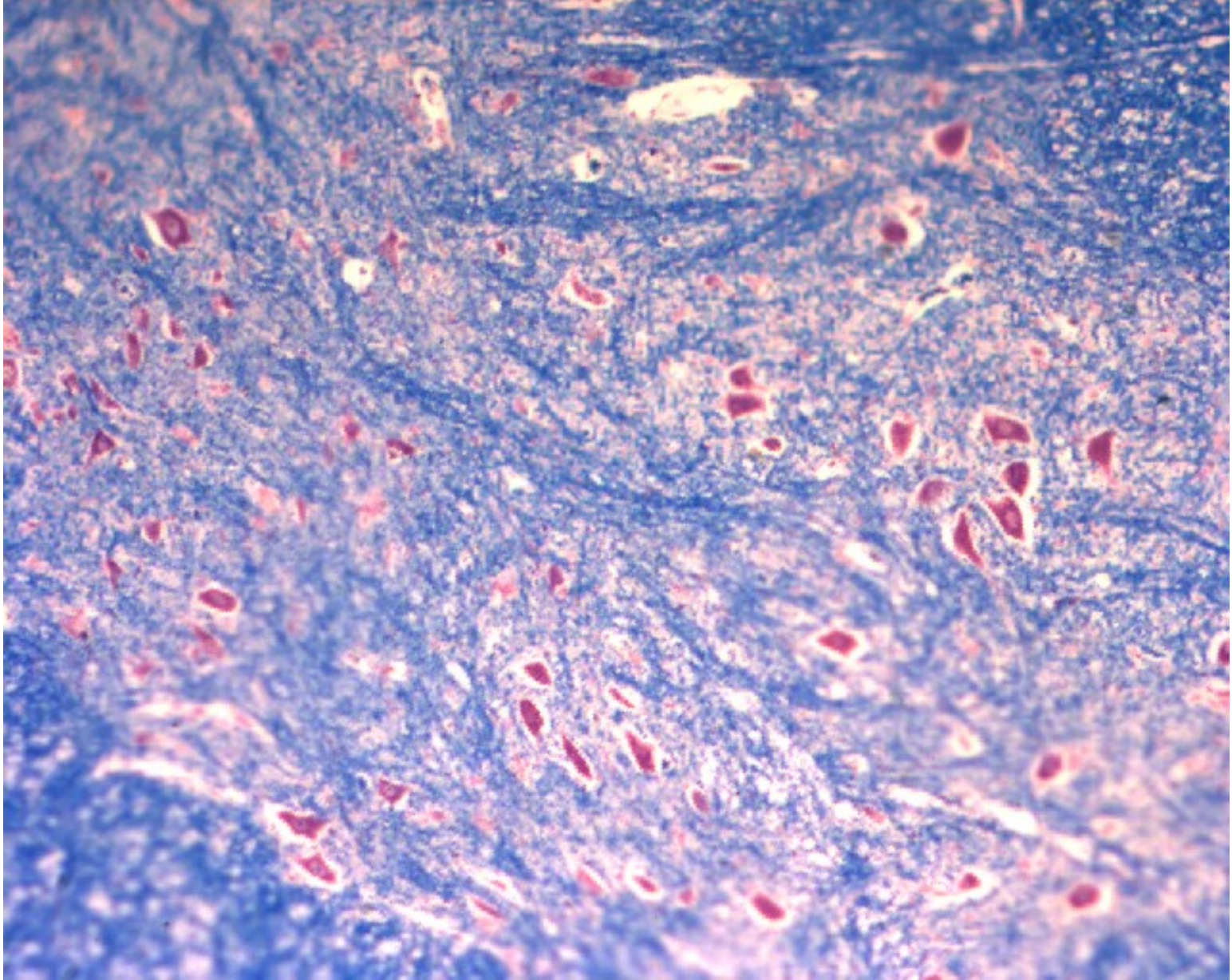
**motor end plate**



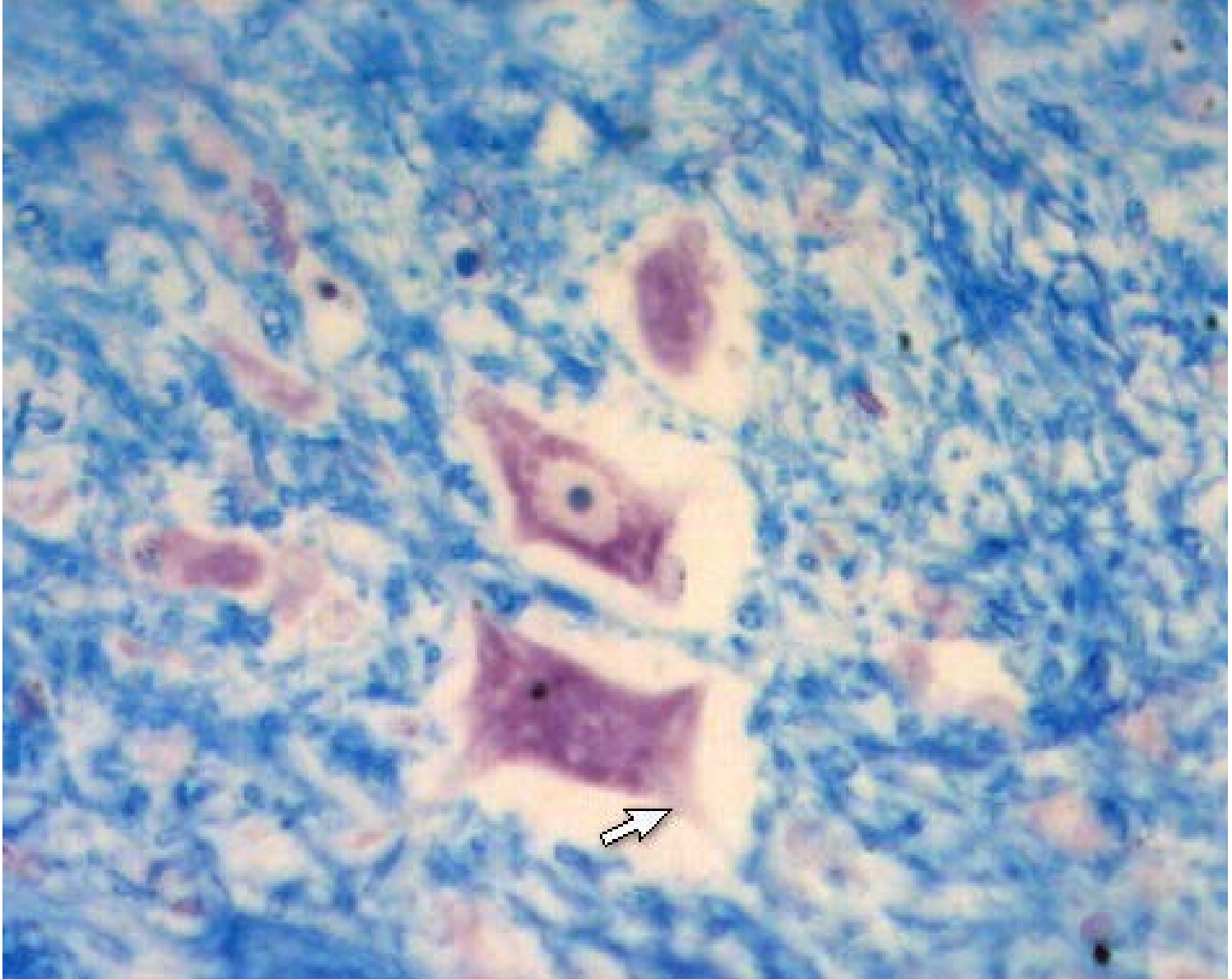
**motor end plate**



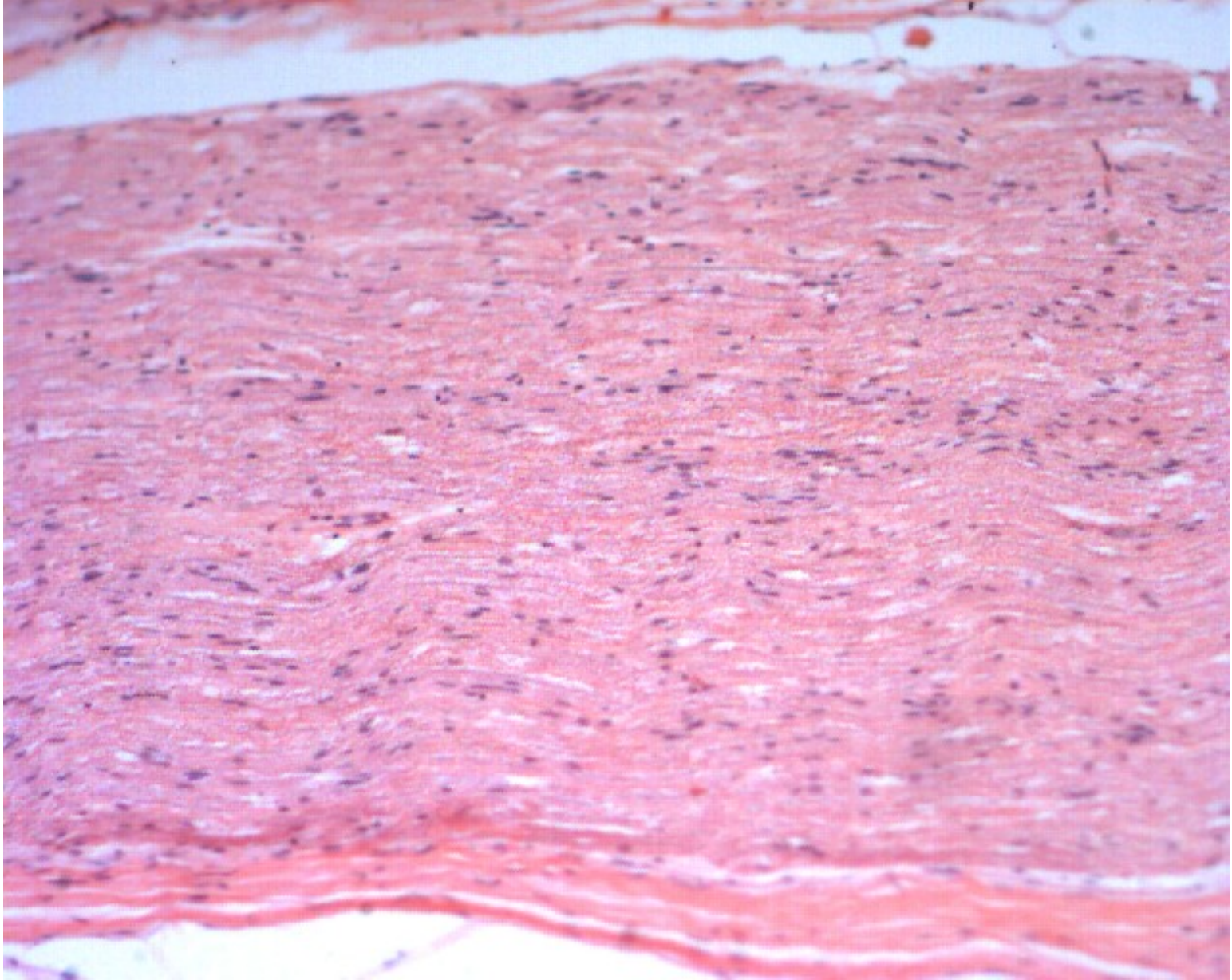
**spinal cord**



**neuron**

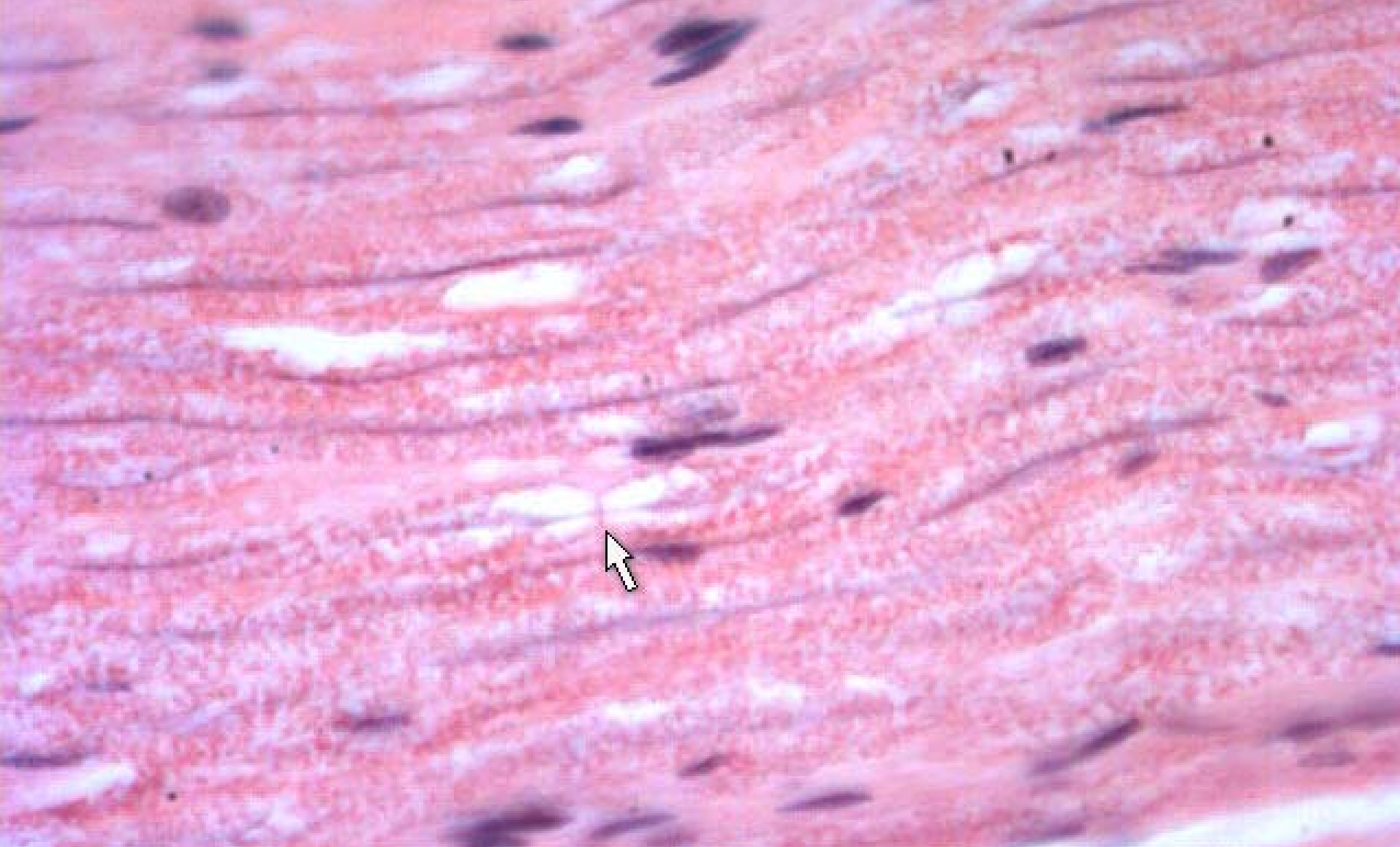


**neuron**

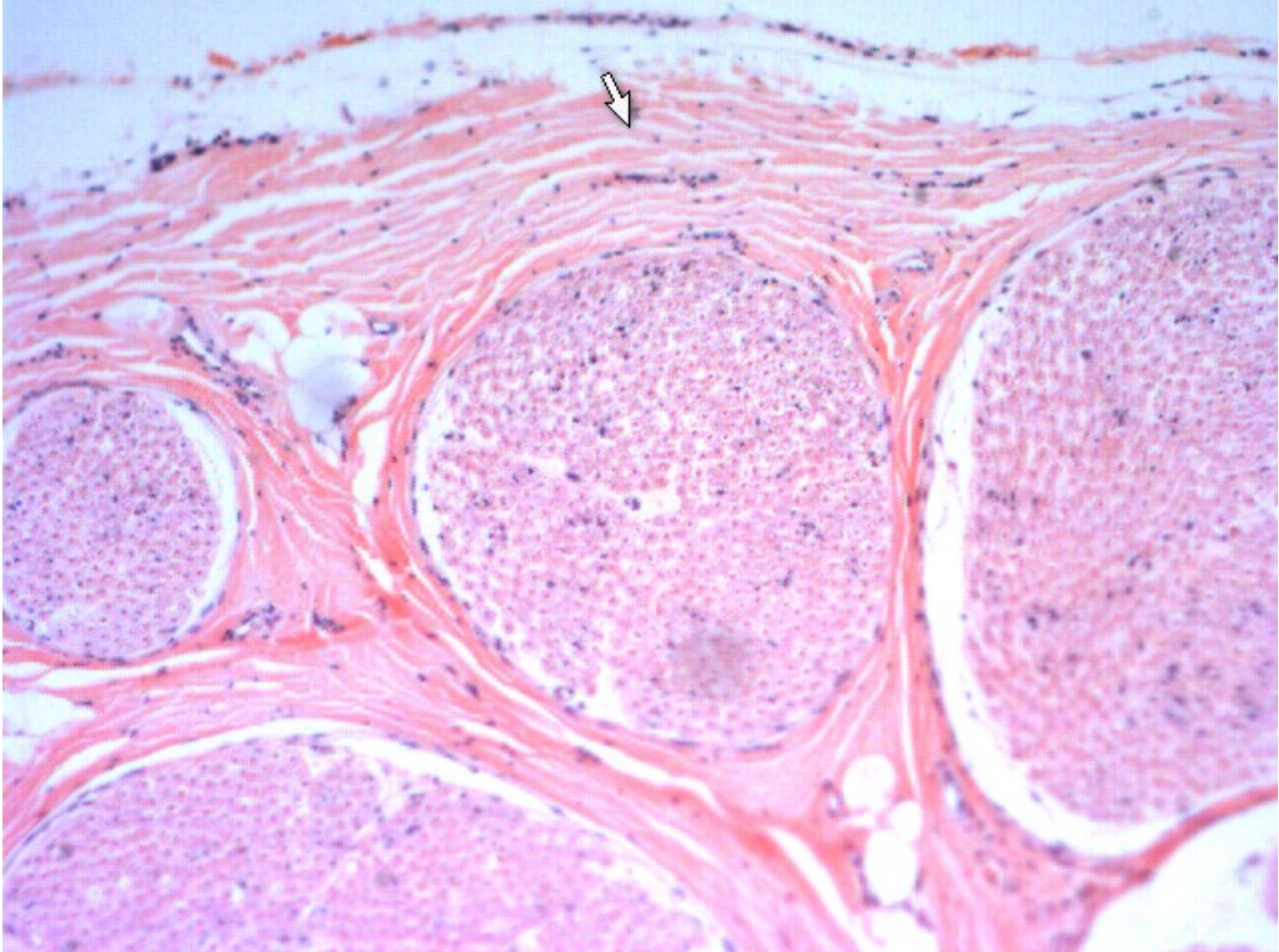


**nerve**

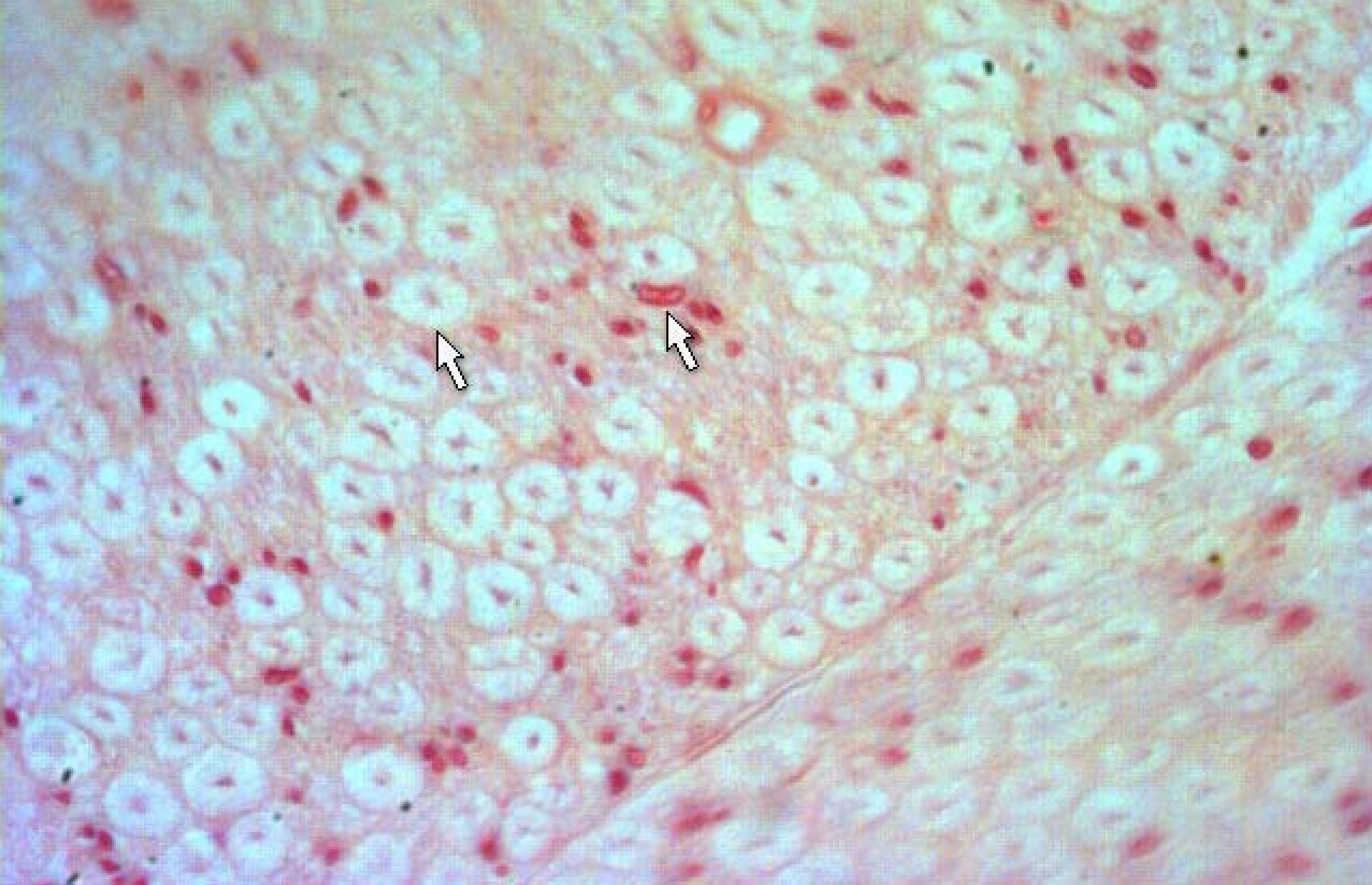




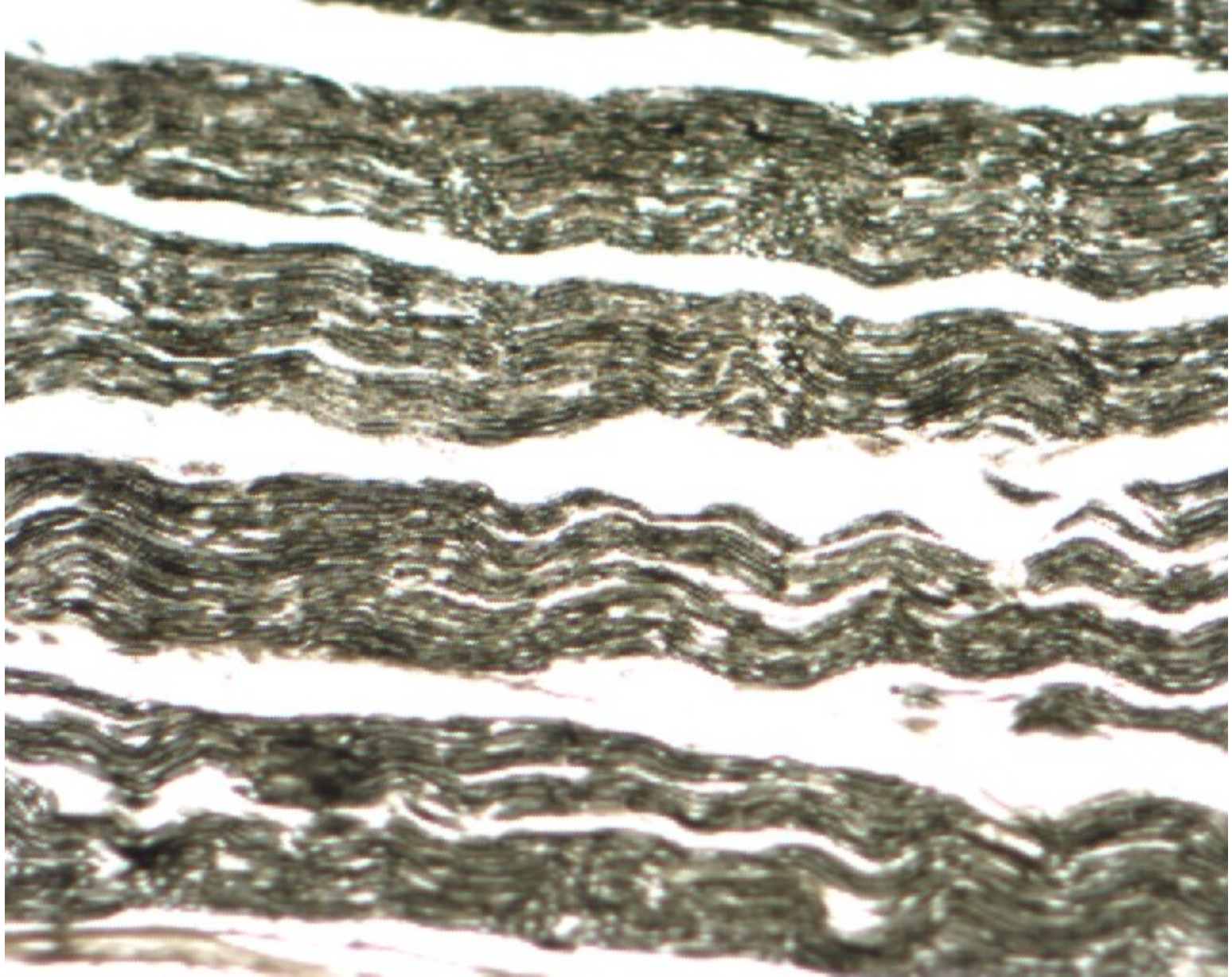
**Ranvier node**



**nerve**



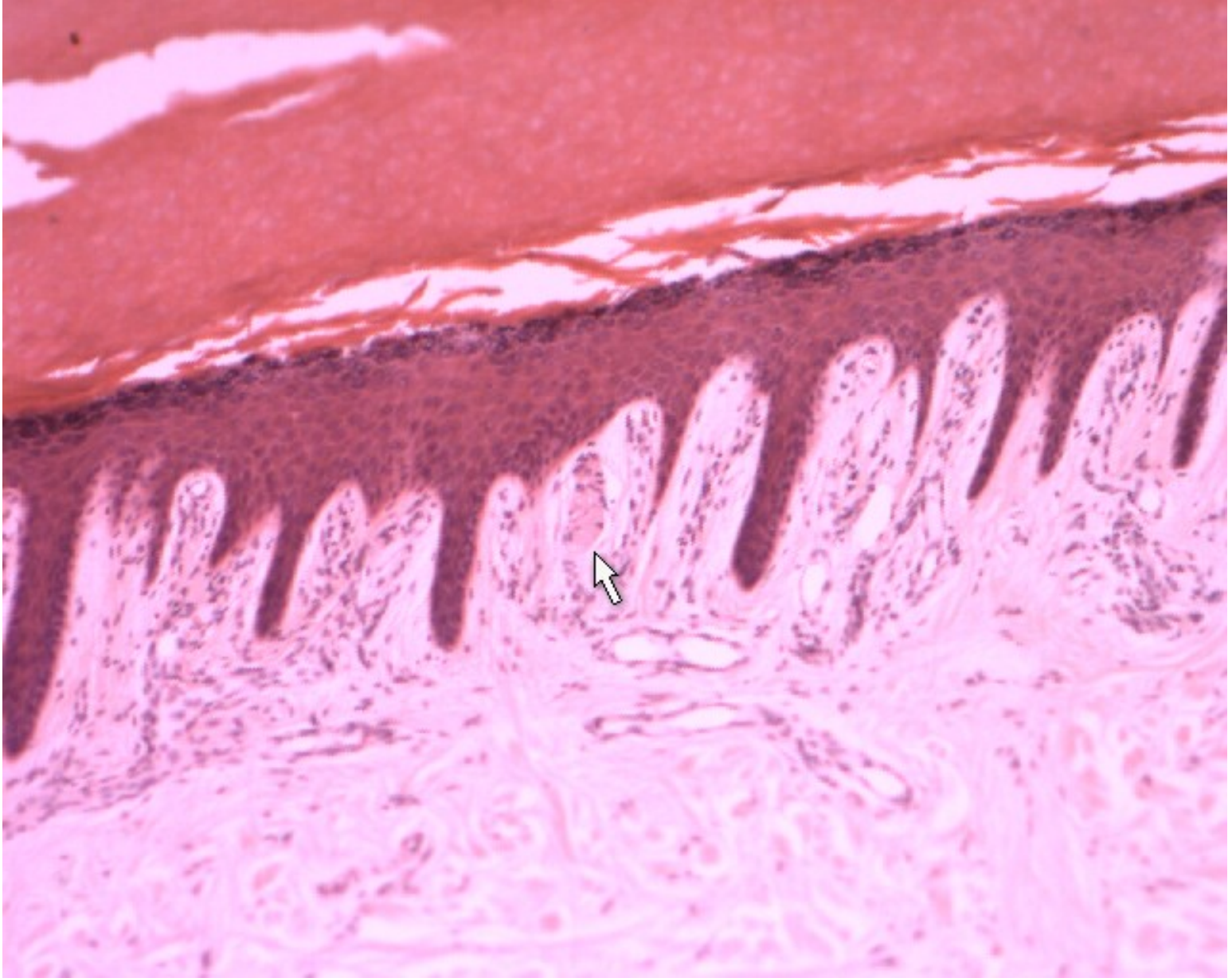
**myelinated nerve fiber and Schwann cell**



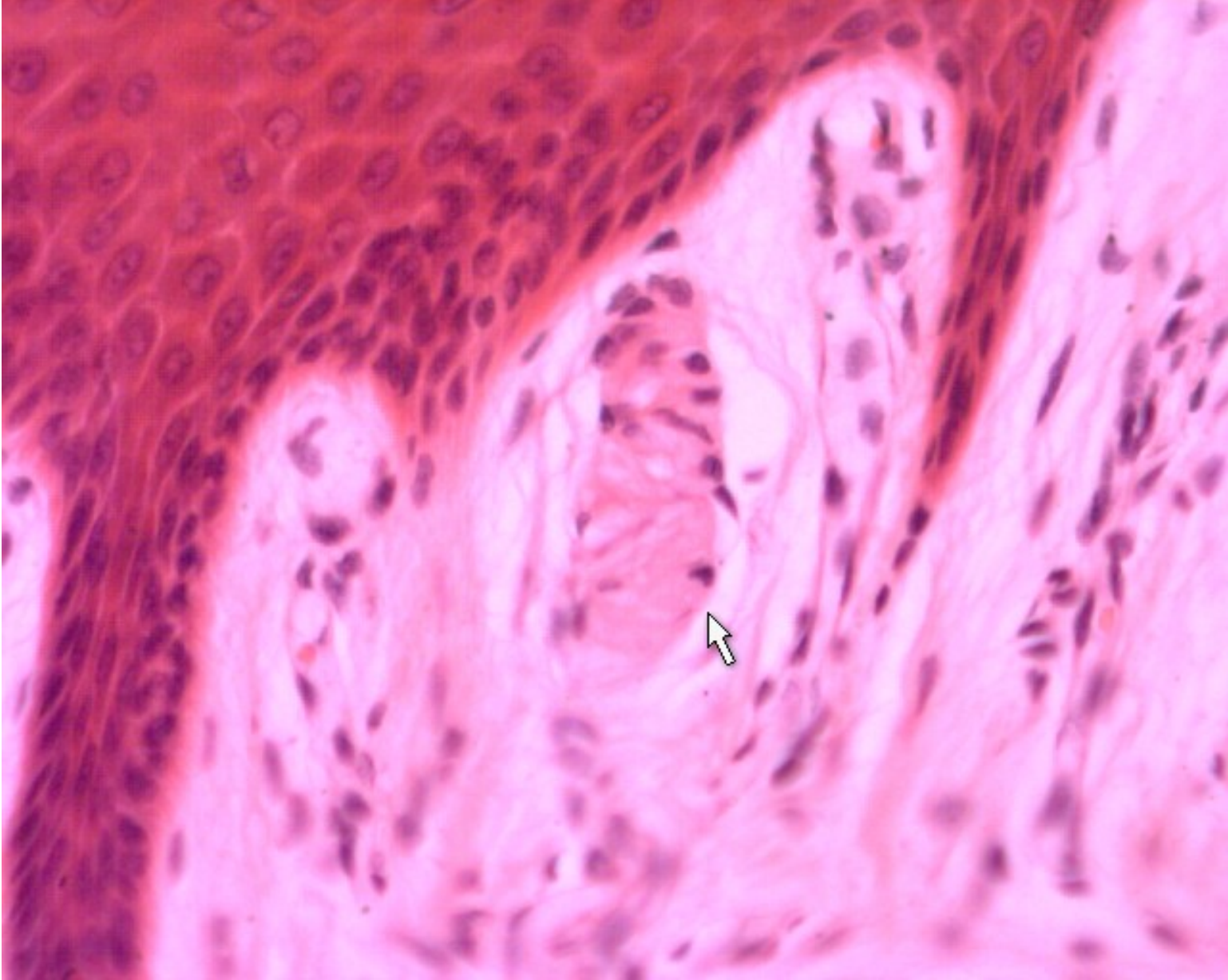
**myelinated nerve fiber**



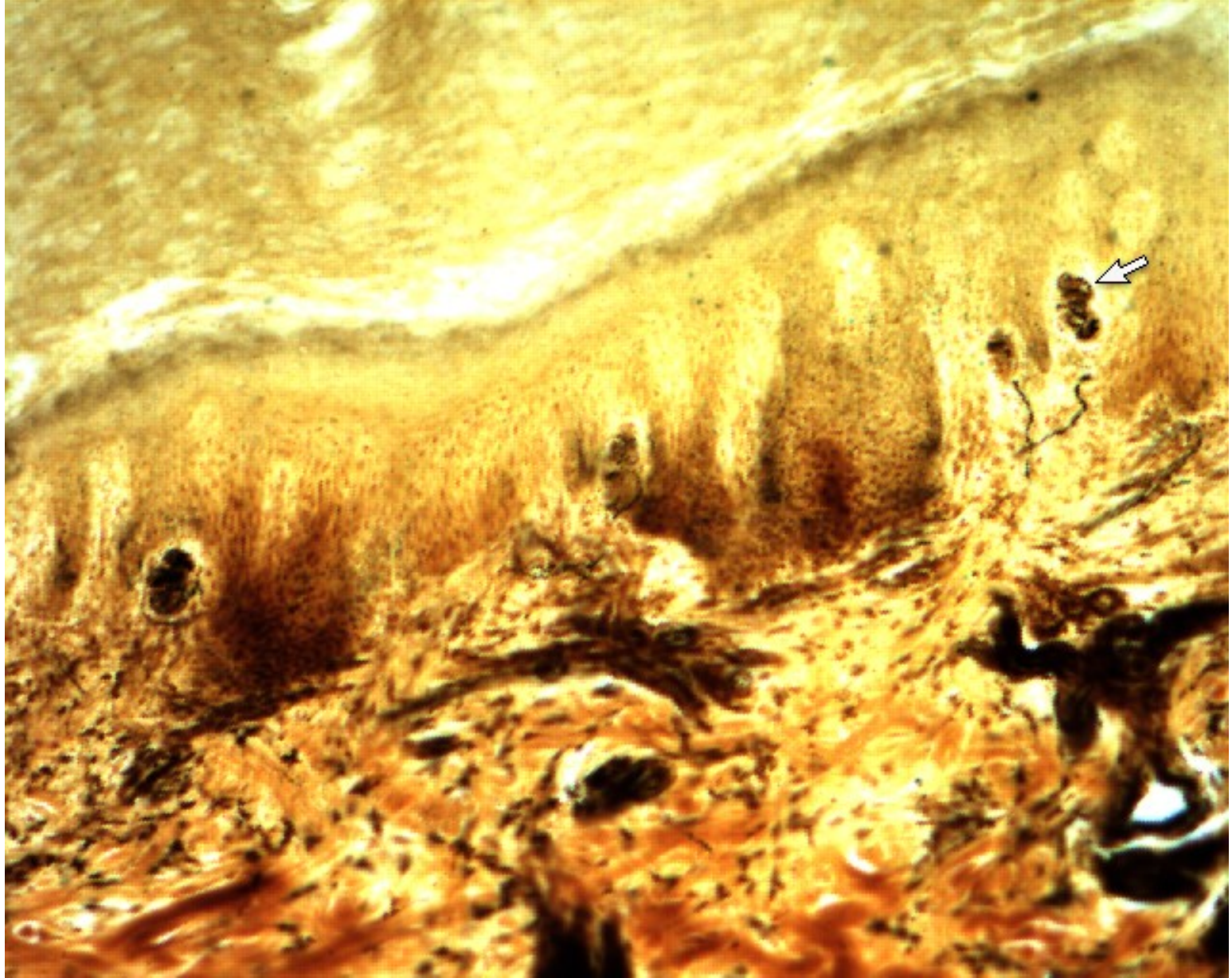
**Ranvier node**



**tactile corpuscle**

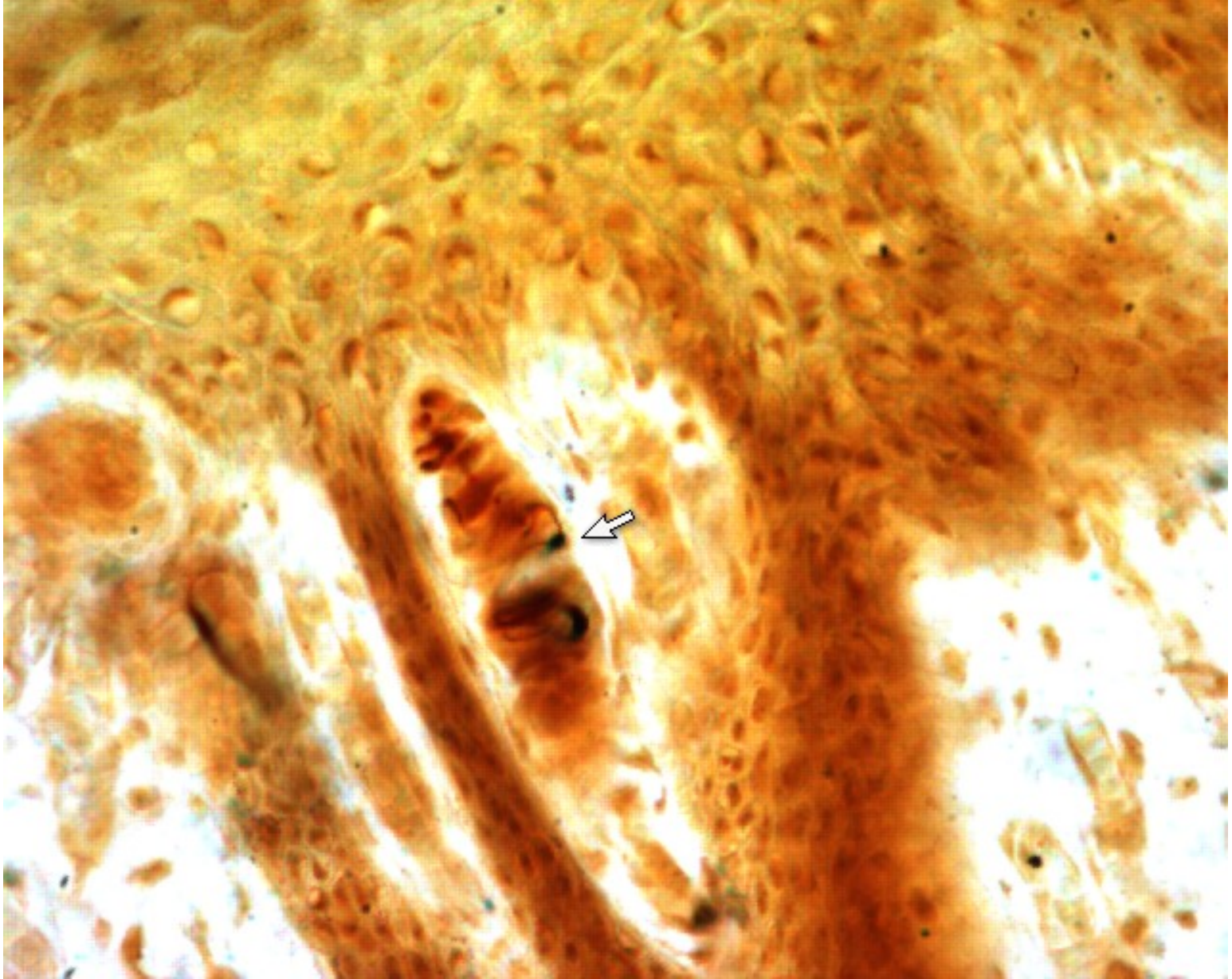


**tactile corpuscle**

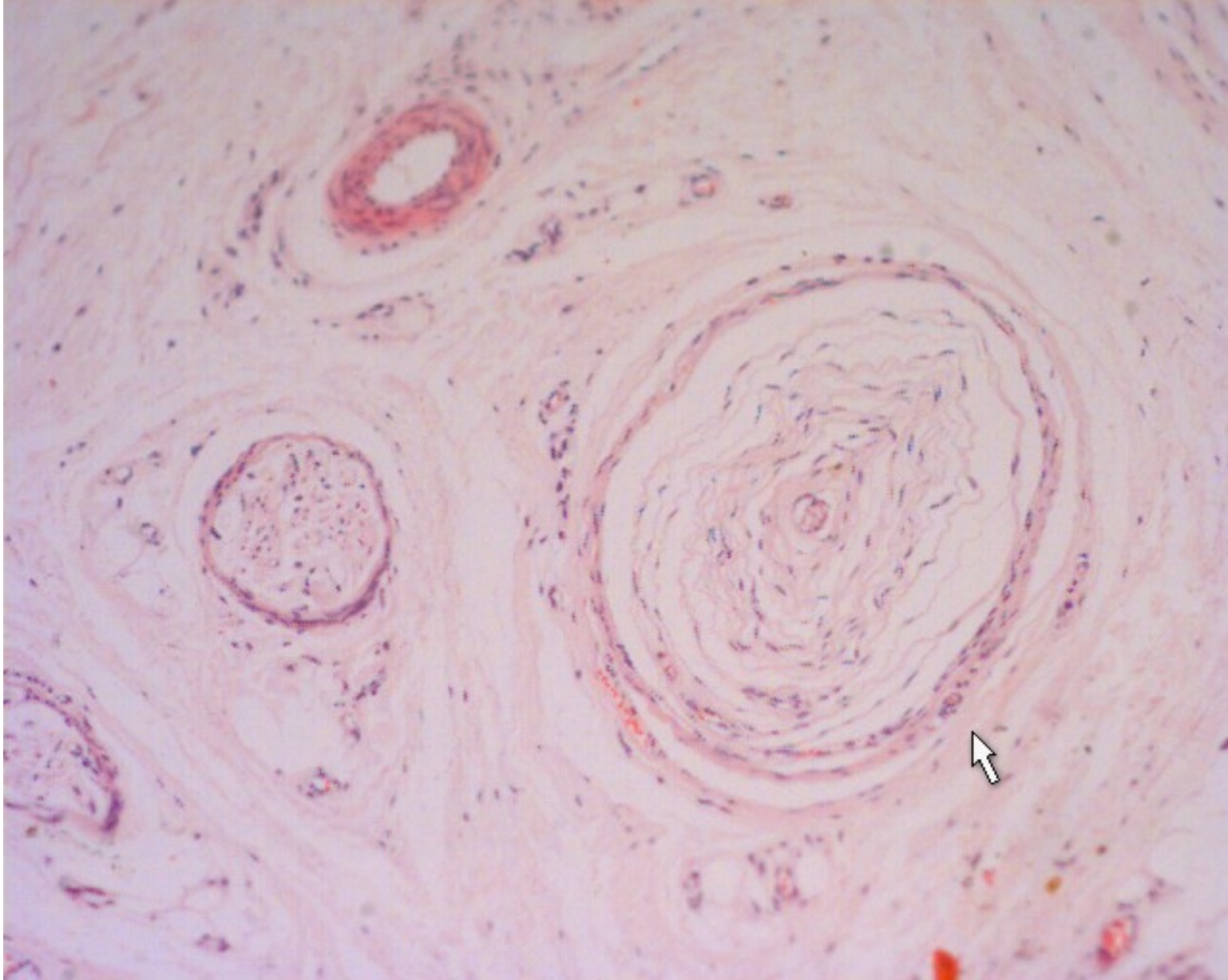


**tactile corpuscle**

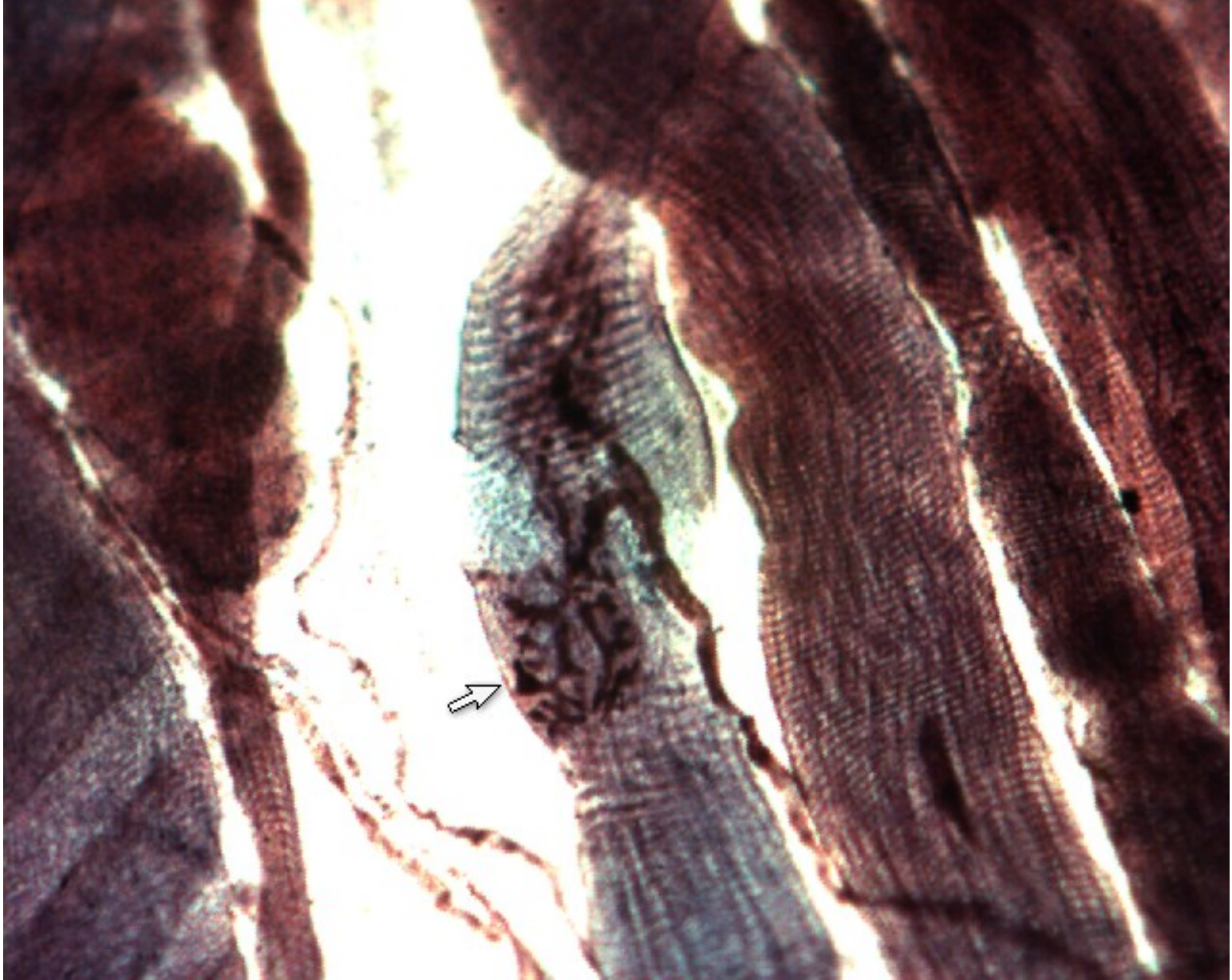



**Tactile corpuscle**



**lamellar corpuscle**



**motor end plate**